

*Skin involvement in highly malignant non-Hodgkin lymphomas of childhood and adolescence**

A. Reich, G. Wróbel, B. Kazanowska, J. Maldyk, H. Bubala, A. Dłużniewska, J. Stefaniak, K. Stefanska, and M. Stolarska

ABSTRACT

Objective: The aim of this study was to demonstrate the clinical spectrum of highly malignant cutaneous non-Hodgkin lymphoma (NHL) in children and to define the outcome among these patients.

Material and methods: A retrospective analysis of children with NHL treated at Polish oncology centers was carried out in order to determine patients with skin involvement. Thirteen subjects with primary and 4 with secondary cutaneous NHL were studied. The diagnosis of NHL was based on histological and immunohistochemical examination of skin biopsy.

Results: Nine of 13 cases of primary cutaneous NHL presented as a tumors. Other manifestations were as follows: hard infiltration, edema of subcutaneous tissue, maculopapular lesions, and generalized erythroderma. The mean time between the first cutaneous symptoms and diagnosis of NHL was 5.6 ± 3.3 months. Secondary cutaneous lesions during the course of NHL were described as maculopapular or nodular eruption. In addition, 2 subjects had generalized ichthyosis. Among patients with primary cutaneous NHL, 11 (84.6%) subjects are still alive without any signs of the disease. Two children (15.4%) died. In patients with secondary skin involvement during the course of NHL only one child is still alive with a residual tumor mass in the mediastinum. The estimated 5-year overall survival for primary cutaneous NHL was significantly better than for individuals with secondary cutaneous NHL ($p = 0.02$).

Conclusions: Primary cutaneous NHL has a relatively favorable prognosis. On the other hand, cutaneous metastases of extracutaneous NHL seem to be a poor prognostic factor.

Introduction

Cutaneous non-Hodgkin lymphomas (NHL) are rare conditions in children and adolescents, only sporadically reported in the literature. A recent study by Fink-Puches et al. (1) clearly documented that the most commonly diagnosed cutaneous NHL among children is

mycosis fungoides (MF), which constitutes nearly 40% of all primary cutaneous NHL (1). Primary cutaneous CD30+ lymphoproliferative disorder, with its two variants: lymphomatoid papulosis (LP) and anaplastic large cell lymphoma (ALCL), is the second most common

KEY WORDS

children,
lymphoma,
outcome,
skin

*National multi-center study of the Polish Pediatric Leukemia/Lymphoma Study Group

Table 1. Clinical data for the patients with cutaneous non-Hodgkin lymphoma.

Pat-ient	Sex	Age (years)	Diagnosis	Cutaneous manifestation of lymphoma	Tumor size	Lymph node involvement	Internal organ involvement	Symptoms on admission (except skin lesions)
1	Male	3	ALCL	Livid tumor with central ulceration on the anterior surface of the left thigh	5 cm	Cervical and inguinal	Bone marrow	Fever
2	Male	8	ALCL	Vast, very hard infiltration of the skin and subcutaneous tissue of the chest, right axilla and right arm	> 10 cm	Axillary and retroperitoneal	Lungs, pleura, liver, spleen	Very poor general condition, paleness, respiratory failure, tachypnea, tachycardia, paralysis of the brachial plexus
3	Female	12	ALCL	Tumor of the back located medially in the area of Th10-Th12 vertebrae (the tumor was initially handled as a furuncle)	4.5 × 3 × 1.9 cm	None	None	None
4	Female	12	ALCL	Edema of subcutaneous tissue and redness of the right upper limb, subsequent necrotic lesions of the right upper limb (arm and upper part of forearm) (the lesions were primarily treated as erysipelas)		Axillary (right side), supraclavicular (right side), submandibular, mesenteric	Mediastinum, spleen, bones (right scapula, humeral bones, femoral bones, left ilium)	Very poor general condition, respiratory failure
5	Male	16	ALCL	Solitary focus of maculopapular lesions with some scaling and a subcutaneous infiltration	> 10 cm	Cervical and axillary	None	None
6	Female	6	Diffuse large B-cell lymphoma	Painful, livid tumor of the skin and subcutaneous tissue of the right axilla	6 cm	None	None	None
7	Female	11	Diffuse large B cell lymphoma	Erythrodermia (the disease was primarily handled as generalized pustular psoriasis)	3.5 cm	None	Bones (skull bones)	Poor nasal patency, facial deformation
8	Female	13	Diffuse large B-cell lymphoma	Soft tumor of the scalp with hair loss in affected area and temporary discharge of mucopurulent exudates (the tumor was initially handled as a lipoma)	-	Cervical (right side)	None	None
9	Male	16	Diffuse large B-cell lymphoma	Soft, jelly-like, subcutaneous tumor of the right subclavicular area; the covering skin was initially unchanged, but after some time became livid-colored	2 × 2.5 cm	None	None	Fever, lack of appetite, weight loss (6 kg)
10	Female	9	Extranodal NK/T-cell lymphoma	Tumor of the right superciliary area	2 × 3 cm	None	None	None
11	Male	15	NK-cell lymphoma, blastic variant	Hard, red tumor of the right lower leg, 5 cm below the knee; in the inferior pole of the tumor a 2 cm, oval ulceration was present	8 cm	Inguinal	None	Pain of the right knee, fever, edema of elbow, ankle and right knee joints
12	Male	12	T-cell lymphoblastic lymphoma	Solitary tumor of the pretibial area, subsequent development of the multiple nodules on the whole body surface	3 × 3 cm	Generalized lymphadenopathy	Bone marrow	Lack of appetite, osteocopic pain, difficulty of breathing
13	Male	13	T-cell lymphoblastic lymphoma	Tumor of the right preauricular area	5 × 1.8 × 3 cm	Retroauricular (right side)	None	None
14	Female	2	ALCL	Ichthyosis and diffuse maculopapular lesions and infiltrations on the whole body surface	-	Cervical, axillary, supraclavicular	Mediastinum, lungs, pleura, pericardium, liver, spleen, intestine	Very poor general condition, fever, signs of respiratory failure
15	Female	11	ALCL	Tiny, maculopapular lesions on the whole body area	-	Generalized lymphadenopathy	Mediastinum, lungs, pleura, liver, spleen, bone marrow	Pruritus, loss of weight, cough, fever, poor general condition
16	Male	15	ALCL	Diffuse nodules and small infiltrations on the whole body surface	0.5-1.5 cm	Cervical, axillary, supraclavicular	Mediastinum, lungs, pleura, liver, spleen, bone marrow, bones (vertebral column)	Fever, very poor general condition
17	Male	17	ALCL	Livid tumor of the neck, smaller nodules on the pubic mound and right shoulder, ichthyosis and papular lesions on the whole body surface	1.5 × 1 cm (the biggest cutaneous lesion)	Generalized lymphadenopathy	Mediastinum, liver	Abdominalgia, pain in the sacral area

ALCL – anaplastic large cell lymphoma

group of primary cutaneous NHL in patients under 20 years of age (1). MF and LP generally have a good outcome and in most cases dermatologists treat these diseases, at least in their early stages, with a combination of topical agents and phototherapy (2–5). Other types of primary cutaneous NHL in children are much more rarely found and most literature documents only one or a few pediatric patients (1, 6–8). Our experience shows that they may demonstrate more aggressive behavior and therefore these NHL are mostly treated in oncology departments with the help of multi-agent chemotherapy. On the other hand, in most cases dermatologists are the first physicians to see these patients because cutaneous lesions are the first signs of the disease. Therefore, despite their rarity, every clinician that deals with skin diseases must keep in mind that children may develop aggressive cutaneous NHL because only a quick and proper diagnosis offers such patients the chance of a cure.

Because published data about highly malignant cutaneous NHL in children and teenagers are scant, we performed a retrospective analysis of patients suffering from NHL in order to demonstrate the clinical spectrum of highly malignant cutaneous NHL in children and to define the outcome among patients with these malignancies.

Patients

A retrospective analysis of children and adolescents with NHL registered by the Polish Pediatric Leukemia/Lymphoma Study Group was carried out in order to determine patients with skin involvement at the time of diagnosis. Although the concept of primary cutaneous lymphoma is related to the diagnosis of lymphoma in a skin lesion when extracutaneous involvement is excluded by an adequate staging for at least 6 months, we believe that in the case of very aggressive NHL this last criterion may result in false classification of true primary cutaneous tumors with rapid progression to the secondary cutaneous NHL. Therefore, in our study subjects with isolated cutaneous NHL or NHL with skin lesions that preceded the appearance of extracutaneous involvement of the disease by at least 1 month were classified in the primary cutaneous NHL group. All other patients were classified as suffering from secondary cutaneous NHL.

All patients were also subdivided according to NHL subtype into three subgroups with different therapy strategies: ALCL, B-cell NHL (NHL-B), and non-B-cell NHL (NHL-NB). A total of 334 cases of NHL were reported by the time of data collection (November 2005): 78 subjects with ALCL, 146 with NHL-B, and 110 with NHL-NB. The Polish database was started in June 1989 for ALCL, in December 1993 for NHL-B, and in August

1993 for NHL-NB. Only clinical data on individuals with NHL that presented cutaneous involvement at diagnosis were chosen for further analysis.

Diagnosis and staging

Biopsy of skin lesions was performed in every patient. The diagnosis of NHL was initially established by a local pathologist and then confirmed by a reference pathologist (J. Malyk) based on histological examination, immunohistochemistry, and in some cases on cytogenetic tests according to the WHO classification of cutaneous NHL (9). If the patients had been classified previously according to other nomenclature, we tried wherever possible to reassess the histology in order to unify the classification. In addition, in some patients lymph node biopsy and/or cytological and immunological examination of cells from malignant effusions were done. The clinical staging of the disease was performed according to the Murphy staging system (10).

Treatment

The patients evaluated were treated according to three separate protocols depending on the subtype of NHL: LCAL-93 for ALCL subjects, LMB-89 for NHL-B, and BFM-90 for NHL-NB (11–13). When possible, resection of the malignancy was performed before chemotherapy.

The patients with ALCL treated according to LCAL-93 protocol received short-pulse chemotherapy with six 5-day courses of multi-drug agents: three A courses (a combination of dexamethasone, ifosfamide, methotrexate (Mtx), cytarabine (Ara-C), and etoposide) and three B courses (combination of dexamethasone, cyclophosphamide, Mtx, doxorubicine). The duration of treatment was approximately 4 to 5 months (11).

Patients with NHL-B were treated according to the LMB-89 protocol (12). All subjects analyzed belonged to two therapeutic groups: patients with a resected tumor in stage I received two courses of COPAD (combination of vincristine, cyclophosphamide, adriamycin, prednisone). The entire course of therapy lasted approximately 6 weeks. The rest of the patients with NHL-B received treatment of 3.5 months' duration with two courses of COPADM (COPAD treatment + high dose Mtx) followed by two courses consisting of Ara-C and Mtx (12).

The patients with NHL-NB received a seven-drug induction phase for the first 9 weeks (prednisone, vincristine, daunorubicin, L-asparaginase, cyclophosphamide, Ara-C, and 6-mercaptopurine), followed by an 8-week consolidation phase: four courses of 6-mercaptopurine and high dose Mtx (5g/m²), and a 2-month

reinduction phase (doxorubicin, dexamethasone, vincristine, L-asparaginase, 6-thioguanine, cyclophosphamide, and Ara-C). All patients continued the next maintenance treatment with 6-mercaptopurine and low dose Mtx until completing a total therapy duration of 24 months (13).

Statistical analysis

The statistical analysis was performed using *Statistica 6.0*® for Windows®. Kaplan-Meier overall survival (OS) was calculated from the date of the start of therapy until the final follow-up or death from any cause. The differences between the curves were estimated by log rank test and *p*-values less than 0.05 were considered to be significant.

Results

In the Polish Pediatric Leukemia/Lymphoma Study Group database, 13 patients were found to have pri-

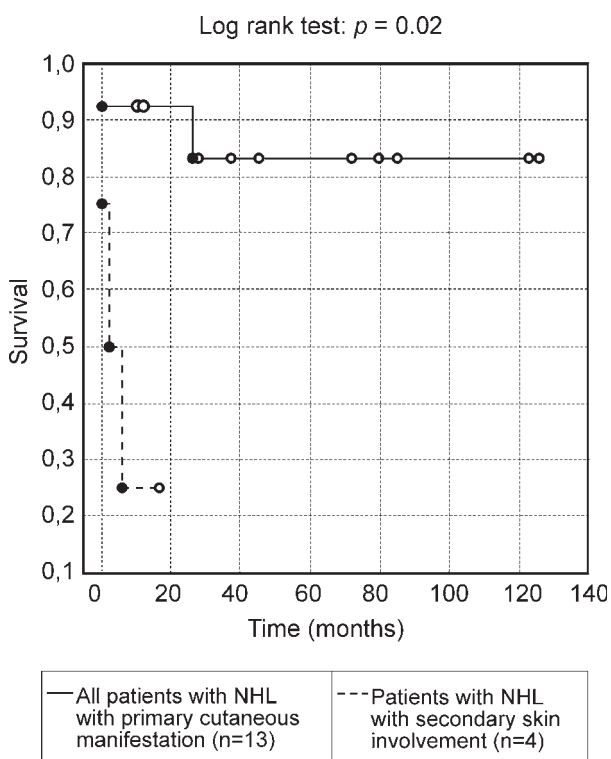


Figure 1. Comparison of overall survival between patients with primary and secondary cutaneous non-Hodgkin lymphomas (NHL).

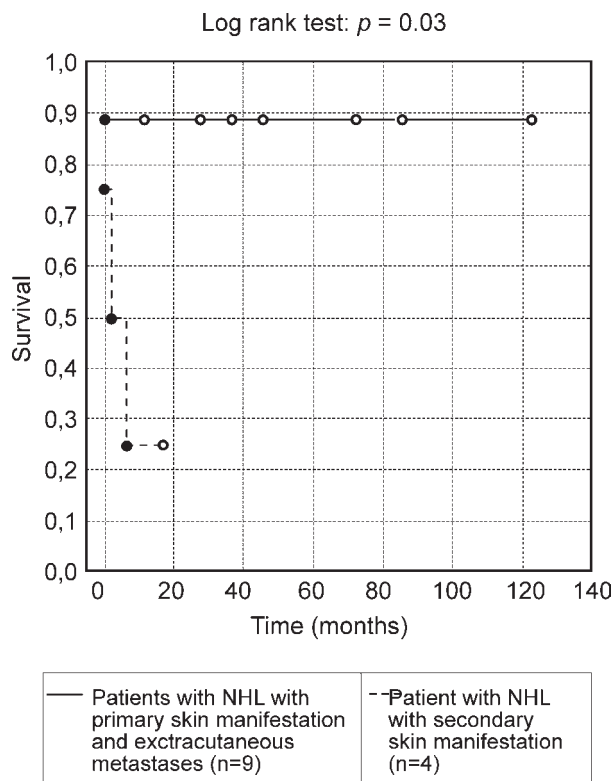


Figure 2. Comparison of overall survival between patients with primary cutaneous non-Hodgkin lymphomas (NHL) with concomitant extracutaneous metastases and patients with extracutaneous NHL with metastases to the skin: patients with primary cutaneous lymphomas, even with distant metastases, had significant better prognosis than patients with secondary cutaneous NHL.

mary cutaneous NHL: 5/78 ALCL, 4/146 NHL-B, and 4/110 NHL-NB. No LP or MF was diagnosed in the group studied. There was no gender predominance (7 boys and 6 girls). In addition, there were four patients (2 boys and 2 girls) with non-cutaneous NHL that presented skin metastases at the time of diagnosis (secondary cutaneous NHL). All these patients were diagnosed as having ALCL (Table 1). The mean age for patients with primary cutaneous NHL was 11.2 ± 3.9 years (range 3–16 years) and for NHL with secondary skin manifestation 11.2 ± 6.7 years (range 2–17 years). The mean observation time for individuals with primary cutaneous NHL was 51.8 ± 40.9 months (range 1–126 months) and for subjects with secondary cutaneous NHL 3.7 ± 2.6 months (range 1–6 months).

Table 2. Classification and outcome in patients with cutaneous non-Hodgkin lymphoma.

Pat- ient	Histological diagnosis	Immunohistochemistry and cytogenetic	Stage (acc. to Murphy et al.)	Cutaneous involvement	Resection of tumor before chemotherapy	Time to diagnosis (months)	Outcome (observation time in months)
1	ALCL, small cell variant, T-cell type	CD7(+), CD20(-), CD30(+), CD43(+), CD45RO(+), ALK-1(+), EMA(+), Granzyme B(+), t(2;5) (-)	IV	Primary	No	5	No evidence of disease (36)
2	ALCL	Not available	III	Primary	No	1	No evidence of disease (11)
3	ALCL, small cell variant, T-cell type	CD20(-), CD30(+), CD43(+), ALK- 1(+), EMA(+), t(1;2) (+)	I	Primary	Yes	3	No evidence of disease (37)
4	ALCL, null-cell type	CD20(-), CD30(+), CD43(+), ALK- 1(+), EMA(+), LCA(+) weak, t(2;5) (+)	IV	Primary	No	4.5	No evidence of disease (72)
5	ALCL, small cell variant, T-cell type	CD20(-), CD30(+), ALK-1(+), EMA(+), CD45RO(+/-), t(2;5) (-)	III	Primary	Yes	No data	No evidence of disease (27)
6	Diffuse large B-cell lymphoma	CD20(+), IgM λ (+), IgM κ (-), LCA(+) weak, CD45RO(+) weak	I	Primary	Yes	No data	No evidence of disease (126)
7	Diffuse large B cell lymphoma, plasmoblastic variant	CD20(+), CD30(-), ALK-1(-), EMA (-), IgM(-), LCA(+), LMB/EBV(+/- some of the cells), Ki67(+ 50% of cells), plasma-cell marker (+)	IV	Primary	No	8	Death because of sepsis in active sta- ge of lymphoma (1)
8	Diffuse large B-cell lymphoma, lympho- plasmotomic variant	Not available	II	Primary	No	5	No evidence of disease (121)
9	Diffuse large B-cell lymphoma, centro- blastic variant	Not available	II	Primary	Yes	5	No evidence of disease (78)
10	Extranodal NK/T-cell lymphoma	CD 2(+), CD43(+), CD45(+), CD56(+), LCA(+), LMP-1/EBV(+), granzyme B(+).	II	Primary	No	No data	Death because of local relapse (25)
11	Extranodal NK/T-cell lymphoma, blastic variant	CD3(-), CD20(-), CD30(-), CD43(+), CD56(+), CD68(-), ALK-1(-), EMA(-), LCA(+)	II	Primary	Only inguinal lymph nodes	6	No evidence of disease (84)
12	T-cell lymphoblastic lymphoma	CD1a(-), cCD3(weak +), CD20(-), D43(+), CD68(-), ALK-1(-), LCA(+), TdT(+), CD45RO(+)	IV	Primary	No	12	No evidence of disease (44)
13	T-cell lymphobla- stic lymphoma	sCD3(-), CD20(-), CD45RO(+), EMA(-), LCA(+), TdT(+)	II	Primary	Yes	No data	No evidence of disease (12)
14	ALCL, small cell variant, T-cell type	No available	III	Secondary	No	No data	Death because of disease progression (2)
15	ALCL	cCD3(+), CD20(-), CD30(+), ALK-1(+)	IV	Secondary	No	1	Death because of disease progression (1)
16	ALCL, common va- riant, null-cell type	CD30(+), ALK-1(+), EMA(+), CD45RO(-)	IV	Secondary	No	No data	Death because of disease local relapse (6)
17	ALCL, mixed variant (common and small cell variants compo- nents)	CD30(+), CD43(+), ALK-1(+), Granzyme B(+), EMA (+/some of cells)	III	Secondary	No	3	Residual tumor mass in mediastinum (16)

Clinical manifestation and laboratory examination

Most primary cutaneous NHL (9/13) presented primarily as soft or hard tumors, sometimes with ulceration in the center of the lesion. In one patient hard

infiltration of the skin and subcutaneous tissue was noted, in one edema of subcutaneous tissue, in one solitary focus of maculopapular lesions with some scaling and concomitant subcutaneous infiltration, and in one generalized erythroderma. The mean time between first cutaneous symptoms and correct diagnosis of NHL was 5.6 ± 3.3 months (range 1–12 months). It is worth

mentioning that in some patients the lesions were incorrectly handled, sometimes over a long period of time, as furuncles or lipomas (tumorous NHL), erysipelas (edematous lesions), and even generalized pustular psoriasis (erythrodermic NHL). Only in 4/13 subjects with primary cutaneous NHL was the skin the only localization of the disease at the time when the diagnosis of NHL was established. In 8/13 individuals, regional or generalized lymphadenopathy was found. In addition, five children had distant metastases: two in the bone marrow, one in the bones, one in the lungs, pleura, liver, and spleen, and one in the mediastinum, spleen, and bones. Regarding the clinical stage of the disease, two patients (15.4%) with primary cutaneous NHL were classified as having stage I, five (38.5%) as stage II, 2 (15.4%) as stage III, and the remaining four (30.7%) as stage IV. A detailed description of the patients and their concomitant clinical symptoms are given in Tables 1 and 2.

The skin lesions in all patients with secondary cutaneous NHL were described as maculopapular eruptions or small infiltrations, sometimes with the formation of small nodules or tumors. In addition, two subjects had generalized ichthyosis (Table 1). There were two (50%) patients in stage III and two (50%) in stage IV (Table 2).

Leukocytosis was observed in 2/13 patients with primary and 3/4 with secondary cutaneous NHL, whereas one patient with primary cutaneous NHL had leukopenia. Thrombocytopenia was observed in only one patient with secondary cutaneous NHL and anemia was noted in two children with primary and two with secondary cutaneous NHL. Elevation of lactate dehydrogenase (LDH) above the upper normal limit (> 300 U/l) was found in 5/13 subjects with primary and 1/4 with secondary cutaneous NHL.

Treatment and outcome

Resection of the tumor was performed before chemotherapy in five (38.5%) patients. In one subject removal of regional lymph nodes was carried out (Table 2). Radiotherapy was not given to any subject. As described in the "Methods" section, almost all children received multi-agent chemotherapy. Only patient number 3 did not receive any systemic treatment. This girl underwent primary removal of the cutaneous lesion at a regional hospital. Three months later she was sent for an oncology consultation with a diagnosis of NHL. For 3 months there was no sign of disease recurrence and no lymph node or internal organ involvement, and therefore it was decided not to apply chemotherapy and only to observe the patient. This subject is still alive without any signs of malignancy (Table 2).

In another patient (patient 4), allogenic bone marrow transplantation was performed after multi-agent chemotherapy. This was done because the girl had been

treated for erysipelas with systemic antibiotics and corticosteroids for several months, until the correct diagnosis of ALCL was made. During her subsequent chemotherapy we observed a delay in the achievement of complete remission, which might be due to steroid resistance in malignant cells. So far, the patient remains in good general condition without any signs of ALCL.

The most commonly observed adverse effects due to chemotherapy were leukopenia (11 patients), various infections (9 patients), liver dysfunction (8 patients), thrombocytopenia (7 patients), anemia (6 patients), and ulcerous stomatitis (6 patients).

Among all patients with primary cutaneous NHL, 11 (84.6%) subjects are still alive without any signs of malignancy. Two other (15.4%) children died: one patient with extranodal NK/T-cell lymphoma due to progression of the disease (local relapse), and one with diffuse large B cell lymphoma due to sepsis, which developed during the first cycle of induction treatment. This patient died with the features of active disease.

Among all children with secondary cutaneous NHL the common subtype ALCL was established, and in all of them a mediastinal mass was identified at diagnosis. Analysis of the outcomes for these patients showed only one child to be alive at the most recent follow-up (16 months after disease diagnosis). This patient still has a residual tumor mass in the mediastinum. All other patients with cutaneous metastases also presented lung and pleura involvement at diagnosis, and all of them died due to disease progression (2 subjects) or local disease recurrence (1 subject; Table 2).

The estimated 5-year overall survival for all patients with primary cutaneous NHL was 0.83 and the prognosis for them was significantly better than for individuals with secondary cutaneous NHL ($p = 0.02$; Figure 1). In addition, even among patients with primary cutaneous NHL that also developed distant metastases the prognosis was significantly better than in patients with extracutaneous NHL with skin metastases ($p = 0.03$; Figure 2). It should be emphasized that so far no patient with secondary cutaneous NHL has lived longer than 2 years. There were no significant differences in overall survival between patients with ALCL, NHL-B, and NHL-NB ($p = 0.64$, data not shown).

Discussion

It is estimated that patients with cutaneous NHL account for about 1% of all subjects admitted to pediatric oncology departments (14). However, because the published data on cutaneous NHL in children (except MF and LP) are very scant and, in most instances, only case descriptions have been reported (6–8, 15, 16), it is difficult to define the prognosis in this group of patients and to elaborate a strategy of treatment. Therefore, these children are very often treated like all other extranodular

NHL cases, with multi-drug chemotherapy and in some cases with surgery (11–13). However, observations made among adult patients suggested that at least some primary cutaneous NHL may have a much better prognosis than other types of NHL (9, 17, 18).

In a recent study by Fink-Puches et al. (1) a large cohort of young patients with cutaneous NHL was demonstrated; however, this study did not concentrate on treatment and outcome of the patients. To the best of our knowledge, our study is the first one to evaluate the prognosis of children with cutaneous NHL other than MF and LP in such a large group of patients.

The estimated overall survival ratio for all patients with primary cutaneous NHL analyzed in this study was high and generally similar to previously reported data in literature on children with different subtypes of nodal or extranodal NHL (11–13, 19). In the primary cutaneous ALCL subgroup the prognosis seems to be very good even for disseminated lymphomas because all of our patients achieved complete remission and are still alive without evidence of disease. However, this subgroup was small and any conclusions must be drawn with caution. Although in adult patients only about 10% of primary cutaneous ALCL present extracutaneous dissemination (9), it seems that this ratio for pediatric patients could be higher because in our group 4/5 patients manifested peripheral lymphadenopathy and 3/5 also had distant metastases. Other authors have also demonstrated pediatric patients with disseminated primary cutaneous ALCL (20, 21).

The main problem with cutaneous involvement in ALCL is determining whether it is primary or secondary. For the adult form of ALCL it is believed that primary cutaneous ALCL does not express epithelial membrane antigen (EMA) and anaplastic lymphoma kinase-1 (ALK-1) (9). However, it was clearly documented by Hinshaw et al. (6) that primary cutaneous ALCL in children may demonstrate chromosomal translocation t(5;2)(p23;q35) and have a positive reaction to ALK-1. Similarly, one patient with ALCL in our group, who presented with only a skin lesion, reacted positively to ALK-1 and EMA. This patient achieved remission after removal of the tumor only and received no chemotherapy. The differences in immunoreactivity between pediatric and adult tumors could reflect different biological behaviors of these malignancies in children and adult patients. In contradistinction to patients with primary cutaneous ALCL, subjects with secondary skin involvement of ALCL had a very poor outcome and only 1/4 patients is still alive, but with a residual tumor in the mediastinum.

Other primary cutaneous NHL: T-cell lymphoblastic lymphoma (2/2 patients are alive in complete remission) and diffuse large B-cell lymphoma of the skin (3/4 patients are alive in complete remission) also demonstrated good outcomes. Only among patients with extranodal NK/T-cell lymphoma was the responder ra-

tio lower: 1/2 patients died due to the disease. This disease is a very rare type of NHL associated with EBV infection, only sporadically reported in the literature (1, 7, 22). According to Imashuku et al. (7) the optimal therapy for these patients consists of immunotherapy with an etoposide-containing regimen, followed by allogenic hematopoietic stem cell transplantation. Late (over 4 weeks from the diagnosis) introduction of etoposide signals a poor outcome (7).

The very poor outcome in our children with secondary cutaneous NHL (all of the ALCL subtype) seems to confirm the experiences in the treatment of systemic ALCL, which suggests that skin, mediastinum, lung, liver, and spleen involvement may be associated with increased risk of treatment failure (11).

A very important aspect that may influence the prognosis of children with cutaneous NHL is the early and proper diagnosis of the malignant lesions. Unfortunately, many patients in our study were misdiagnosed and improperly treated for several months. This is true not only for cutaneous NHL, but also for other malignancies arising within the skin in children (23). We believe that the main reason for this fact is that malignant skin lesions in children are frequently highly uncharacteristic.

Conclusions:

1. Malignant skin lesions in children are very rare, variable, and frequently highly uncharacteristic.
2. The final diagnosis of malignant skin lesions is often delayed.
3. We propose performing a biopsy in every pediatric patient with a suspicious skin lesion, especially in cases in which the patient does not respond to the initial treatment.

List of abbreviations

ALCL	anaplastic large cell lymphoma
ALK-1	anaplastic lymphoma kinase-1
Ara-C	cytarabine
cCD3	cytoplasmatic CD3 antigen,
COPAD	combination treatment regimen consisting of vincristine, cyclophosphamide, adriamycin and prednisone.
COPADM	combination treatment regimen consisting of COPAD treatment and high dose methotrexate
EBV	Epstein-Barr virus
EMA	epithelial membrane antigen
LCA	leukocyte common antigen,
LDH	lactate dehydrogenase
LMP-1	latent membrane protein-1,
LP	lymphomatoid papulosis
MF	mycosis fungoides
Mtx	methotrexate

NHL	non-Hodgkin lymphoma	sIg	surface immunoglobulin,
NHL-B	B-cell non-Hodgkin lymphoma	TdT	terminal deoxynucleotidyl transferase
NHL-NB	non-B-cell non-Hodgkin lymphoma		
OS	overall survival		
sCD3	surface CD3 antigen,		

Note

All of the authors declare that they do not have any relevant financial interest in this article.

REFERENCES

1. Fink-Puches R, Chott A, Ardigó M, Simonitsch I, Ferrara G, Kerl H, Cerroni L. The spectrum of cutaneous lymphomas in patients less than 20 years of age. *Pediatr Dermatol* 2004; 21: 525–33.
2. Nijsten T, Curiel-Lewandrowski C, Kadin ME. Lymphomatoid papulosis in children. A retrospective cohort study of 35 cases. *Arch Dermatol* 2004; 140: 306–12.
3. Van Neer FJMA, Toonstra J, Van Voorst Vader PC, Willemze R, Van Vloten WA. Lymphomatoid papulosis in children: a study of 10 children registered by the Dutch Cutaneous Lymphoma Working Group. *Br J Dermatol* 2001; 144: 351–4.
4. Pabsch H, Rütten A, von Stemm A, Meigel W, Sander CA, Schaller J. Treatment of childhood mycosis fungoides with topical PUVA. *J Am Acad Dermatol* 2002; 47: 557–61.
5. Tan E, Tay Y-K, Giam Y-C. Profile and outcome of childhood mycosis fungoides in Singapore. *Pediatr Dermatol* 2000; 17: 352–6.
6. Hinshaw M, Trowers AB, Kodish E, Kuerbitz S, Shurin S, Wood GS. Three children with CD30+ cutaneous anaplastic large cell lymphomas bearing the t(2;5)(p23;q35) translocation. *Pediatr Dermatol* 2004; 21: 212–7.
7. Imashuku S, Teramura T, Konishi K, Kikuchi A, Tamura S, Maeda Y, Kuroda H. Treatment of Epstein-Barr virus-associated peripheral T-cell lymphoma. *Br J Dermatol* 2004; 150: 1038–40.
8. Ghislanzoni M, Gambini D, Perrone T, Alessi E, Berti E. Primary cutaneous follicular center cell lymphoma of the nose with maxillary sinus involvement in pediatric patients. *J Am Acad Dermatol* 2005; 52: S73–7.
9. Willemze R, Jaffe ES, Burg G, Cerroni L, Berti E, Swerdlow SH, et al. WHO-EORTC classification for cutaneous lymphomas. *Blood* 2005; 105: 3768–85.
10. Murphy SB. Classification, staging and end results of treatment of childhood non-Hodgkin's lymphomas: dissimilarities from lymphomas in adults. *Semin Oncol* 1980; 7: 332–9.
11. Seidemann K, Tiemann M, Schrappe M, Yakisan E, Simonitsch I, Janka-Schaub G, et al. Short-pulse B-non-Hodgkin lymphoma-type chemotherapy is an efficacious treatment for pediatric anaplastic large cell lymphoma: a report of the Berlin-Frankfurt-Munster Group Trial NHL-BFM 90. *Blood* 2001; 97: 3699–706.
12. Patte C. Treatment of mature B-ALL and high grade B-NHL in children. *Best Pract Res Clin Haematol* 2003; 15: 695–711.
13. Grenzbach J, Schrappe M, Ludwig WD, Parwaresch M, Zimmermann M, Gadner H, et al. Favorable outcome for children and adolescents with T-cell lymphoblastic lymphoma with an intensive ALL-type therapy without local radiotherapy. *Ann Hematol* 2001; 80: Suppl 3: B73–6.
14. Buyukpamukcu M, Ilhan I, Caglar M, Akyuz C, Berberoglu S, Kotiloglu E. Skin involvement in children with non-Hodgkin's lymphoma. *Turk J Pediatr* 1995; 37: 117–23.
15. Tomaszewski MM, Moad JC, Lupton GP. Primary cutaneous Ki-1 (CD30) positive anaplastic large cell lymphoma in childhood. *J Am Acad Dermatol* 1999; 40: 857–61.
16. Taniguchi S, Kono T. Subcutaneous T-cell lymphoma in a child with eosinophilia. *Br J Dermatol* 2000; 142: 183–4.
17. Rijlaarsdam JU, Toonstra J, Meijer OW, Noordijk EM, Willemze R. Treatment of primary cutaneous B-cell lymphomas of follicle center cell origin: a clinical follow-up study of 55 patients treated with radiotherapy or polychemotherapy. *J Clin Oncol* 1996; 14: 549–55.

18. Beljaards RC, Kaudewitz P, Berti E, Gianotti R, Neumann C, Rosso R, et al. Primary cutaneous CD30-positive large cell lymphoma: definition of a new type of cutaneous lymphoma with a favorable prognosis. A European Multicenter Study of 47 patients. *Cancer* 1993; 71: 2097–104.
19. Atra A, Imeson JD, Hobson R, Gerard M, Hann IM, Eden OB, et al. Improved outcome in children with advanced stage B-cell non Hodgkin's lymphoma (B-NHL): Results of the United Kingdom Children Cancer Study Group (UKCCSG) 9002 protocol. *Br J Cancer* 2000; 82: 1396–402.
20. Meier F, Schaumburg-Lever G, Kaiserling E, Scheel-Walter HG, Scherwitz C. Primary cutaneous large-cell anaplastic (Ki-1) lymphoma in a child. *J Am Acad Dermatol* 1992; 26: 813–7.
21. Kadin ME, Sako D, Berliner N, Franklin W, Woda B, Borowitz M, et al. Childhood Ki-1 lymphoma presenting with skin lesions and peripheral lymphadenopathy. *Blood* 1986; 68: 1042–9.
22. Shirasaki E, Taniuchi K, Matsushita T, Hamaguchi Y, Takata M, Takehara K. Epstein-Barr virus-associated T-cell lymphoma: a case of eyelid swelling and intramuscular infiltration mimicking dermatomyositis. *Br J Dermatol* 2002; 147: 1244–8.
23. Kazanowska B, Reich A, Jelen M, Jankowski B, Chybicka A. Peripheral primary neuroectodermal tumour of the cubital fossa. *Skin Cancer* 2005; 20: 205–10.

**A U T H O R S '
A D D R E S S E S**

Adam Reich, Department of Dermatology, Venereology, and Allergology, Wrocław University of Medicine, Ul. Chalubinskiego 1, 50-368 Wrocław Poland; e-mail: adi_medicalis@go2.pl
Grazyna Wróbel, Department of Bone Marrow Transplantation, Pediatric Oncology and Hematology, Wrocław University of Medicine, Poland
Bernarda Kazanowska, same address
Jadwiga Maldyk, Department of Pediatric Pathology, Medical University of Warsaw, Warsaw, Poland
Halina Bubala, Department of Pediatric Hematology and Oncology, Silesian Medical Academy, Zabrze, Poland
Agnieszka Dłużniewska, Department of Pediatric Oncology and Hematology, Polish-American Institute of Pediatrics, Jagiellonian University Medical College, Kraków, Poland
Jolanta Stefaniak, Department of Pediatric Hematology and Oncology, Medical University of Lublin, Poland
Katarzyna Stefanska, Department of Hematology and Pediatric Oncology, Poznan University of Medical Sciences, Poland
Malgorzata Stolarska, Department of Pediatric Hematology and Oncology, Medical University of Łódź, Poland