

Reticular form of oral lichen planus. A 19-year observation period in 75 patients from Slovenia

M. Rode, A.A. Kansky and M. Kogoj-Rode

ABSTRACT

Background. 75 patients (60 of them women) with the reticular form of oral lichen planus (OLP) were under observation during a 19-year period.

Methods. The patients had no complaints and were referred to the specialist by their dentist. They were studied at the Department of Clinical Oral Pathology of the Medical Center in Ljubljana.

Results. A remission of the lesions was observed in 24, intensification in 9, while in 42 the lesions persisted. During the period of observation no malignant alteration was observed.

Conclusion. In well-documented cases of the reticular form of OLP the malignant transformation is rare, the differential diagnosis Between OLP and leukoplakia may be however difficult on purely clinical ground. For this reason a biopsy is suggested in such cases.

Introduction

Lichen planus (LP) is a relatively common disorder which affects 0.5% to 1.9% of population. Approximately 20% of patients in a referral oral surgery practice were diagnosed with oral lichen planus (OLP) (1,2).

OLP is a common chronic inflammatory disease of the oral mucous membranes. It is observed on the buccal mucosa, oral vestibule, gingivae and the tongue. It has a variety of clinical appearances: reticular, papular, plaque-like, erosive, ulcerative, bullous and atrophic (3,4,5,6). Reticular OLP is generally characterized by lesions consisting of radiating white or grey papules in a linear, annular or retiform arrangement, forming typical reticular patches, rings and streaks on the oral mucosa. The reticular form is the most common and is gene-

rally asymptomatic, while the ulcerative and bullos forms are frequently associated with pain. Compared with skin lesions, mucosal affections are far more chronic in nature, with less than 20% undergoing complete remission (3).

OLP is histopathologically well defined, characterized by a T cell-dominated infiltrate in proximity to the basal cell layer of the epithelium, by epithelial basal cell destruction and thickening or disruption of the basement membrane (7,8,9,10).

Although the etiology of OLP is very complex and the pathological process remains presently obscure (11), there are indications that it may be associated with stress, some systemic diseases, drugs and immunologic dis-

KEY WORDS

lichen
planus,
reticular,
oral cavity

orders (12). Results of numerous investigations indicate that cell-mediated mechanisms are involved in the initiation and progression of the lesions (13). It is reasonable to assume that OLP is a localized autoimmune disease. Walsh et al. suggest that modified keratinocyte surface antigens are the target for the cytotoxic cell response, whereas mast cells, antigen-presenting Langerhans cells and cytokines produced by lymphocytes and keratinocytes play a key role in the evolving lesion (14). There is an accumulating evidence for the role of TNF- α in OLP (15). Recent studies suggest the involvement of heat shock proteins as autoantigens (15). A number of studies suggest that there is a close relationship between hepatitis C virus infection and OLP in certain groups of patients (16,17).

OLP is important since the possibility of malignant transformation is mentioned in the literature (18,19,20, 21,22), the malignant potential is still questionable. Overexpression of the p53 gene in the OLP samples without gene mutations were reported. This may be a physiological response and may serve to protect against mutagenesis; p53 mutation appears to be an early event in the process of carcinogenesis (23).

There have been a number of mainly retrospective studies from several countries that show only a minimal risk of malignant transformation. In his population-based 10-19 year prospective study Murti et al. (19) reported its malignant transformation as 0.3%, Silverman et al. (14) reported malignant transformation in 1.2%, Holmstrup et al. (22) in 1.5%, Salem (24) in 5.6%, Voute et al. (25) in 2.7%, and Silverman et al. (26) a 2.3% rate of malignant transformation during a mean time of 7.5 years.

Material and methods

Our data on 75 patients are described and compared with those from other studies. Clinical data include age, gender, previous medical history, medications, therapeutic protocol and malignant association.

The data on 75 patients with reticular form of oral lichen were collected from a previous survey by the Department of Clinical Oral Pathology of Medical Centre in Ljubljana. The patients had no complaints and were directed to the specialist by their dentist who had discovered the lesions. From all patients the history of the present OLP, as well as general medical and dental histories were taken. The patients were studied since 1975 and were followed through to 1994. The mean age at the initial presentation was 58.3 years with a standard deviation of 5.1 years. The age range was from 41 to 64 years. Of the 75 patients 60 (80 %) were women. Three investigators double performed the oral examinations of all lesions checking each other in daylight and using the mouth mirror. Oral reticular lichen was diagnosed and registered on a clinical basis. The score of 0-3 was

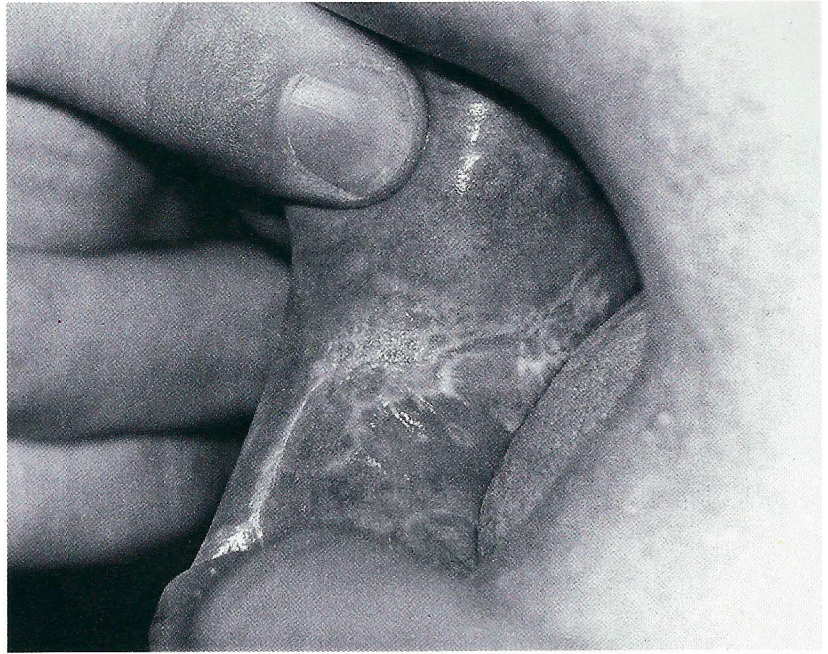


Figure 1: Reticular oral lichen planus: typical lesions on the buccal mucosa.

recorded according to the following criteria:

- Score 0 = no lesions, normal mucosa
- Score 1 = white striae, less than 1 cm²
- Score 2 = white striae, more than 1 cm²
- Score 3 = white striae, more than 2 cm².

Figure 2: Reticular oral lichen planus: a more intense lesion on the buccal mucosa

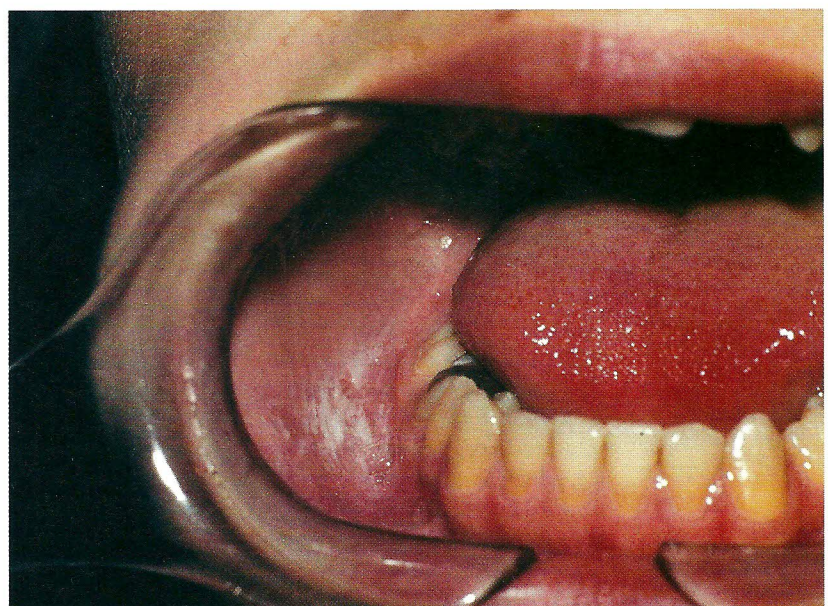

Table 1. Lesion sites in 75 patients with oral lichen planus

Sites	No.
Buccal mucosa	47
Retromolare pad	15
Tongue	10
Floor of the mouth and gingiva	3
All lesions	75

Table 2. Evolution of lesions during a 19-year observation period

Situation	No.
Remission	24
Complete remission	0
Intensification	9
Status quo	42
All changes	75

From all our patients biopsies of lesional oral mucosa were removed under local anesthesia and fixed in 10% formaldehyde solution for routine histopathology. The diagnosis of OLP was confirmed histologically at the Institute of Pathology, Medical Faculty of Ljubljana.

No patient had characteristic skin lesions. Patients with lichenoid lesions close to dental amalgam fillings and patients with oral lichenoid drug eruptions (27) were not included in the group under observation.

The patients were re-examined once every six months and lesions showing clinical changes were registered. Biopsy was repeated after 10 years of observation in 9 patients with a progredient OLP. They received no treatment during the years under observation.

Results

1. Location of the lesions

The primary lesion site was the buccal mucosa, with secondary sites of the retromolar pads, tertiary sites on the tongue and quaternary sites on the floor of the mouth and the gingiva. Multiple lesion sites occurred frequently (Table 1).

2. Lesions' evolution

Disease remission was noted in 24 patients after initial presentation. A more pronounced expression of the lesions was noted in 9 patients and an unchanged situation was observed in 42 patients over a 19-year period after initial observation (Table 2). Transformation

into other forms of OLP was not observed.

3. Histopathologic findings

All tissue specimens showed similar histological abnormalities. The epithelium of the oral mucosa was hyperplastic with acanthotic projections, hyperplasia was seen in the spinous layer; the epithelium was covered by a parakeratotic layer. Liquefaction of the basal cell layer was observed focally, accompanied by marked mononuclear infiltrate at the dermoepidermal junction. No atypia of the epithelial cells was found. Histopathological findings after 10 years of observations were similar to previous findings. No dysplasia was found.

4. No malignant alteration was detected in any of the 75 patients.

Discussion

The data presented are consistent with data from previous studies with regard to location and disease

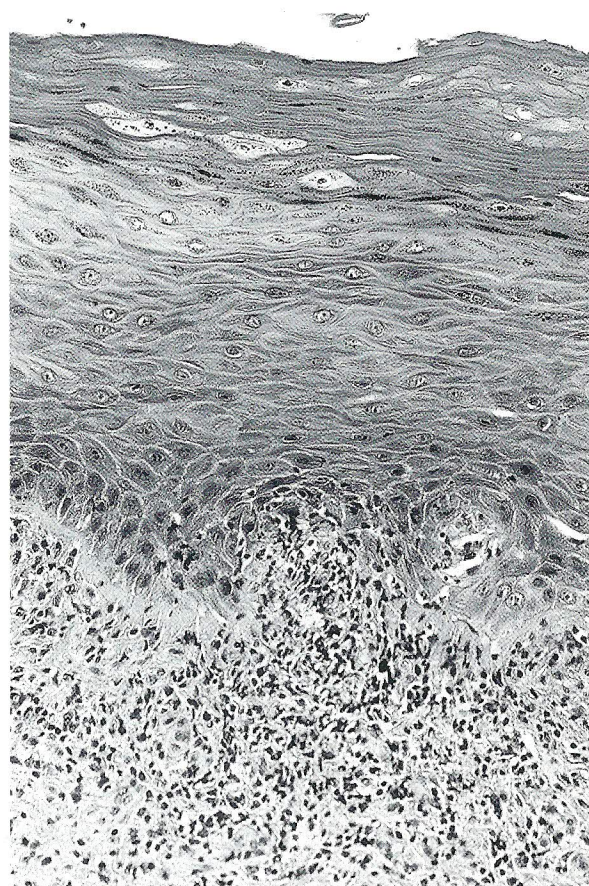


Figure 3: Histopathology of reticular oral lichen planus: parakeratosis, acanthosis, vacuolar degeneration of basal cells, typical lichenoid lymphocytic infiltrate. H.E. x 195.

chronicity (3,14). Disease remission was noted without treatment. Female patients prevailed. The routine biopsy procedure in the diagnosis of OLP is a controversial one (3,28). From all lesions in our study biopsies were routinely taken. All tissue specimens showed similar histological abnormalities. No atypia of the epithelial cells was found.

We recorded no cases of malignant transformation. Our results confirm findings of Brown et al. (3) and do not support the observations of Silverman et al. (20) who reported malignant transformation in one of the cases with reticular OLP. The results of Holmstrup et al. (29,30) who reported that reticular OLP is related to oral cancer could not be confirmed either. Reticular oral lichen planus manifests itself with typical clinical symptoms. There are lesions that clinically do not resemble oral lichen planus but have lichenoid features in histology, and others that clinically resemble oral lichen planus, but show atypia or dysplasia from the onset (26). This may be the source of some of the controversy in the literature concerning its malignant transformation (22), (25). No case of malignant transformation in 75 patients followed up to 19 years was recorded. We recorded disease remission without therapy in 24 patients and intensification of mucosal striae in 9 patients. Our study does not support the observations of Brown et al. (3) or the findings of Thorn et al. (30) who suggested a complete remission.

A malignant transformation of all forms of oral lichen planus cannot be excluded. However, it would therefore

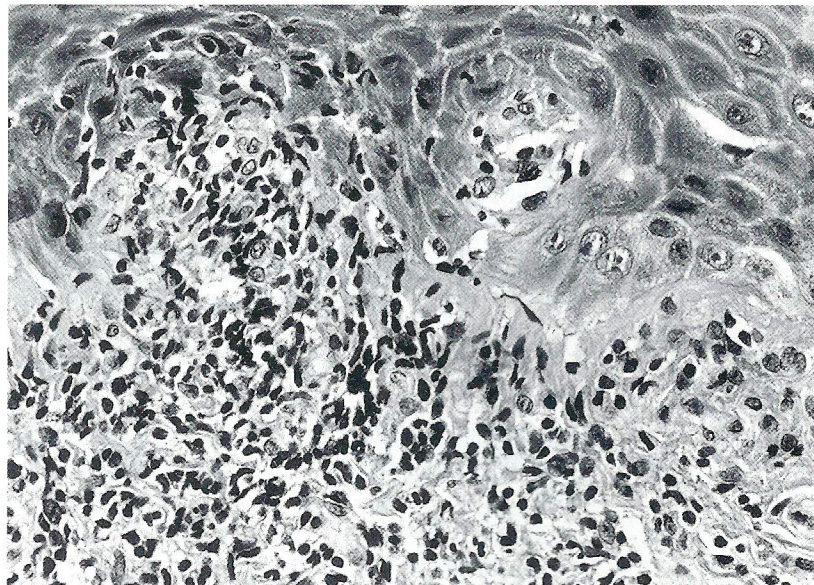


Figure 4: Same as figure 3. H.E. x 250.

seem prudent to confirm the clinical diagnosis of OLP histologically, and to have patients followed up regularly.

Conclusion

It is suggested that a biopsy should be performed in all instances of OLP and that the patients should be followed up regularly.

REFERENCES

1. Brown RS, Bottomley WK, Puente E, Lavigne GL. A retrospective evaluation of 193 patients with oral lichen planus. *J Oral Pathol Med* 1993; 22: 69-72.
2. Scully C, El - Kom M. Lichen planus: review and update on pathogenesis. *J Oral Pathol* 1985; 14: 431-58.
3. Cooke BD. Keratinizing lesions affecting the oral mucosa. *Proc Roy Soc Med* 1967; 60: 819-22.
4. Andreassen JO. Oral lichen planus. *Oral Surg Oral Med Oral Pathol* 1968; 25: 31-42.
5. Thorn JJ, Holmstrup P, Rindum J, Pindborg JJ. Course of various clinical forms of oral lichen planus. *J Oral Pathol* 1988; 17: 213-8.
6. Altman J, Perry HO. Variations and course of lichen planus. *Arch Dermatol* 1961; 84: 179-91.
7. Walsh LJ, Savage NW, Ishi T, Seymour GJ. Immunopathogenesis of oral lichen planus. *J Oral Pathol Med* 1990; 19: 389-96.
8. Silverman S, Gorsky M, Lozada-Nur F. A prospective follow - up study of 570 patients with oral lichen planus. *Oral Surg Oral Med Oral Pathol* 1985; 60: 30-4.
9. Kovesi G, Banoczy J. Follow - up studies in oral lichen planus. *Int J Oral Surg* 1973; 2: 13-22.
10. Silverman S, Griffith M. Studies of oral lichen planus. *Oral Surg* 1974; 37: 705-14.
11. Murti PR, Daftary DK, Bhonsle RB, Gupta PC, Mehta FS, Pindborg JJ. Malignant potential of oral lichen planus. *J Oral Pathol* 1986; 15: 71-7.

