

Acral melanoma after a bitumen burn

R. Peila, A. Poletti, E. Clonfero and C. Veller Fornasa

S U M M A R Y

A case of acral melanoma developed in a 59-year-old man; it was diagnosed 45 days after a bitumen burn had been reported. The relationship between the bitumen burn and the development of the malignant melanoma is discussed.

Introduction

A wide variety of physical and chemical agents and various forms of trauma are considered possible risk factors for malignant melanoma (MM). In particular, there are some data consistent with a relationship between burns and the development of MM (1, 2). In these reports, the interval between burns and the clinical diagnosis of MM was extremely variable (from a few weeks to several years) (2- 4). We report a case of MM which developed a few weeks after a bitumen burn.

30 years. Physical examination revealed an ulcerated plaque approximately 4 cm in its greatest diameter on the plantar surface in of the right heel (Figure 1).

This ulcerative lesion was deep red and with heaped-up borders. The surface was wet and spongy. Two pigmented spots, about 2 mm wide, were present within the lesional area. The patient has been suffering from a severe burn in at the site of the lesion. A careful history failed to demonstrate the presence of a previous pigmented lesion at the site of the burn.

The histopathologic analysis showed the presence of an ulcerated malignant melanoma that was growing vertically and infiltrating the reticular dermis (Clark's level III, Breslow's tumour depth 3,5 mm). The neoplastic cells showed epithelioid features with an obvious peritumoral lymphocytic infiltrate. Immunohistochemical analysis of the skin biopsy revealed that the neoplastic cells were positive for S-100 protein, HMB 45,

K E Y W O R D S

acral
melanoma,
bitumen
burn,
polycyclic
aromatic
hydrocarbons
(PAHs)

Case report

A 59-year-old man presented with a history of bitumen burn on his right sole about 45 days earlier. The man had been carrying asphalt bitumen for about

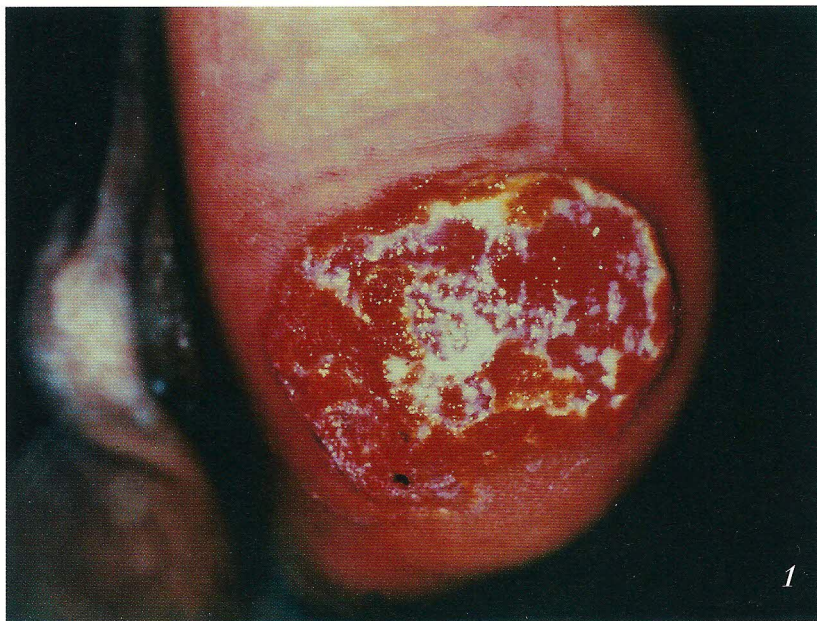

Figure 1. Ulcerative plaque of approximately 4 cm in its greatest diameter on the plantar surface of the right heel. The ulcerative lesion is deep red and with elevated borders. The surface was wet and spongy. Two pigmented spots, about 2 mm wide, could be observed within the lesional area.

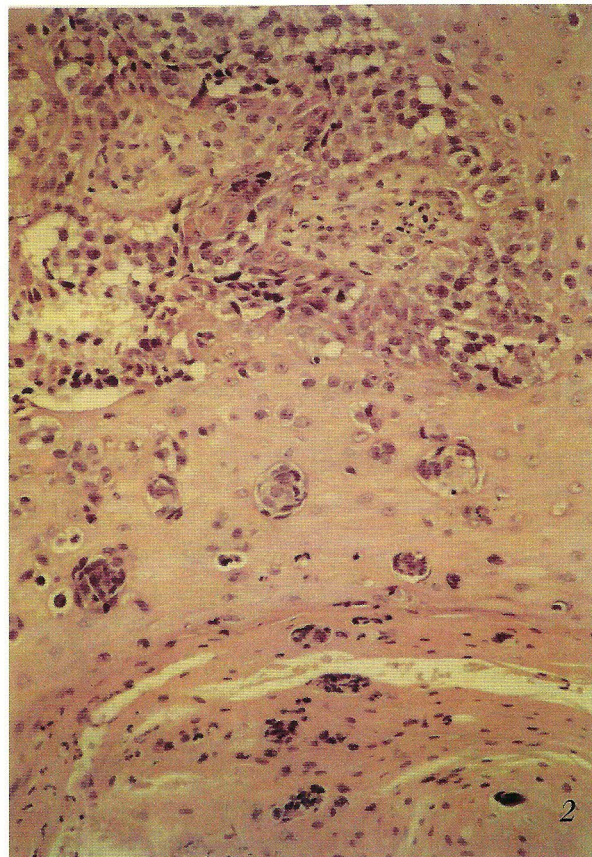
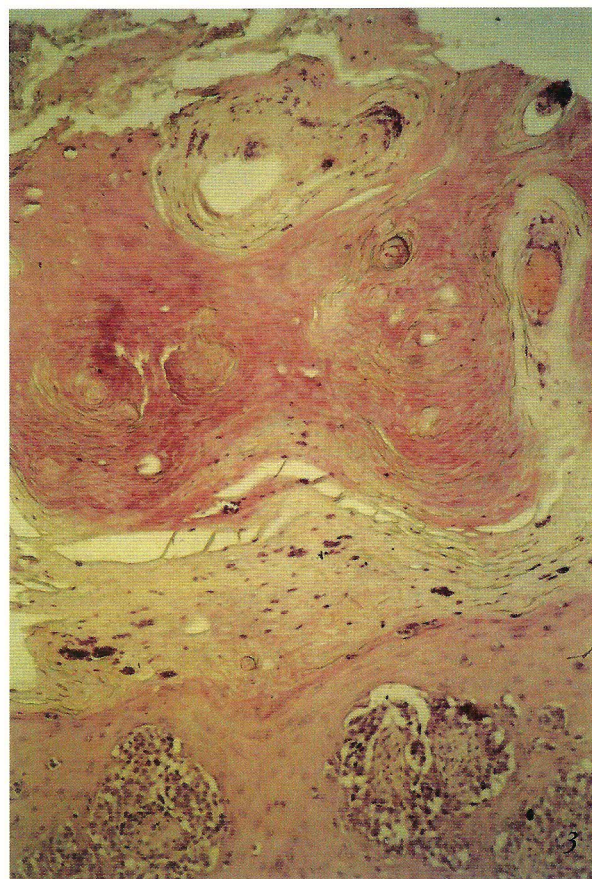

Figure 2. Histopathologic examination of the lesion on the plantar surface of the border. Hyperkeratosis of the epidermal compartment and two nests of neoplastic melanocytes is evident. H&E 25x

Figure 3. Both single and small nests of neoplastic melanocytes can be observed in the epidermal compartment. H&E 70x.



anti-PCNA (85%) and negative for Keratin (AE1/AE3).

The patient died five years after the initial diagnosis.

Discussion

A case of MM, which developed after a burn is reported. It has been impossible to establish if a pigmented lesion existed before the trauma occurred. So far, only a few cases have been reported demonstrating the development of a MM a few weeks after the burn. Most of the MM observed after a burn were evident after several years (3, 4). This long period of latency may be determined by both the characteristics of the scar tissue and the low number of melanocytes in the tissue (1).

The MM of our patient appeared after a short time from the burn and to the best of our knowledge, it is the first case induced by a bitumen burn.

Bitumen contains, even if in small quantities, the polycyclic aromatic hydrocarbons (PAHs) that are a family of aromatic compounds with carcinogenic activity. The PAHs are mutagenic and can act locally by chemical induction of melanoma (1). Some studies show how the PAHs may produce the apparition of MM in animals, both in the hamster after a single topical application of 7,12-dimethylbenc (a)-anthracene (DMBA) at 1% and in the mouse after a single topical application at 0,2% followed by the exposure to other

promoter agents (5). Rockley et al. suggested a relationship between the occupational exposure to PAH(s) and the development of MM (1). Moreover the asphalt contains many other agents with a carcinogenetic potential (6). Mineral oils, also, with a similar composition to bitumen distillates proved to have the same activity (7). As our patient had been carrying asphalt bitumen for about 30 years, it may be possible that the bitumen burn acted as promoter of the MM in a site subjected for several years to carcinogenic initiators. This may also explain the severity of the initiator neoplasm and the short interval between the burn and the development of the MM.

REFERENCES

1. Rockley PF, Trieff N, et al. Nonsunlight risk factors for malignant melanoma. Part I: Chemical agents, physical conditions and occupation. *Int J Dermatol* 1994; 33: 398-406.
2. Delacrètz J, Mevorah B, Pettavel J. Mèlanome malin apparu dans les suites immédiates d'une brulure. *Soc Franç de Derm Syph, Reunion de Paris, Seance du 12 Mars* 1970.
3. Lee JYY, Kapadia SB, Musgrave RH, et al. Neurotropic malignant melanoma occurring in a stable burn scar. *J Cutan Pathol* 1992; 19: 145-50.
4. Delaunay MM, Courouge-Dorcier D, Castède JC. Malignant melanoma occurring on a burn scar. *Ann Dermatol Venereol.* 1991; 118 (2): 129-30.
5. Takizawa H, Sato S, Kitajima H, et al. Mouse skin melanoma induced in two stage chemical carcinogenesis with 7,12-dimethyl-benz-(a)-anthracene and croton oil. *Carcinogenesis* 1985; 6: 921-3.
6. Wey HE, Breitenstein MJ, Toraason MA. Inhibition of intercellular communication in human keratinocytes by fractionated asphalt fume condensate. *Carcinogenesis.* 1992; 13 (6); 1047-50.
7. Agarwal R, Shukla Y, Kumar S, Mehrotra NK. Evaluation of carcinogenic effect of jute batching oil (JBO-P) fractions following topical application to mouse skin. *Arch Toxicol* 1988; 62 (6): 406-10.

A U T H O R S ' A D D R E S S E S *Rossana Peila MD, Department of Dermatology, University of Padova, Via C. Battisti 206, 35128 Padova, Italy*
Alessandro Poletti MD, Department of Pathology, University of Padova
Ernesto Clonfero MD, Institute of Occupational Health, University of Padova, 35128 Padova, Italy
Cleto Veller Fornasa MD, professor of dermatology, Department of Dermatology, University of Padova, 35128 Padova, Italy