

KERATODERMIA PALMOPLANTARIS PAPULOSA (BUSCHKE-FISCHER-BRAUER). CASE REPORT.

M. Košiček, T. Perkovič, T. Lunder, M. Penko and A. Kansky

ABSTRACT

A case of hereditary palmoplantar keratoderma (HPPK) papulosa in a 68-year-old man is presented. The large number of isolated hyperkeratoses symmetrically distributed on the palms and soles appeared at the age of 30 years. The similar changes on the palms and soles had also the patient's father and grandfather as well as his son.

Histologically the lesions consisted of a thickened horny layer with keratotic plugs. There were hypergranulosis and acanthosis. Dermoepidermal junction was normal.

Compared to other types of HPPK, the disease is rare. Until now, sixteen cases have been detected in Slovenia.

KEY WORDS

hyperkeratosis, hereditary, palmoplantar, papular, micromorphology

INTRODUCTION

The term *hereditary palmoplantar keratodermas* (HPPK) includes a number of various clinical types, characterized by the main symptom: hyperkeratoses of the palms and soles (1). The most frequent type seems to be HPPK Unna-Thost, which can not be clinically differentiated from HPPK Vörner type. Certain authors even believe that the majority of Unna-Thost type cases are rather HPPK Vörner type. However, this problem is still not clarified (2, 3). In the group of HPPK other types (nosologic

entities) may be distinguished, e. g. keratosis palmoplantaris transgrediens (Mljet type), keratosis extremitatum hereditaria progrediens, HPPK Papillon-Lefèvre type (4), HPPK Jadassohn-Lewandowsky (pachyonychia congenita) (5), as well as others (1, 6).

HPPK papulosa was first described in 1910 by Buschke and Fischer and later in 1913 by Brauer (7, 8). It is a relatively rare disease. Different synonyms are used: keratosis palmoplantaris papulosa Buschke-Fischer-Brauer, keratoma hereditarium dissipatum palmare et plantare, keratoderma symmetrica

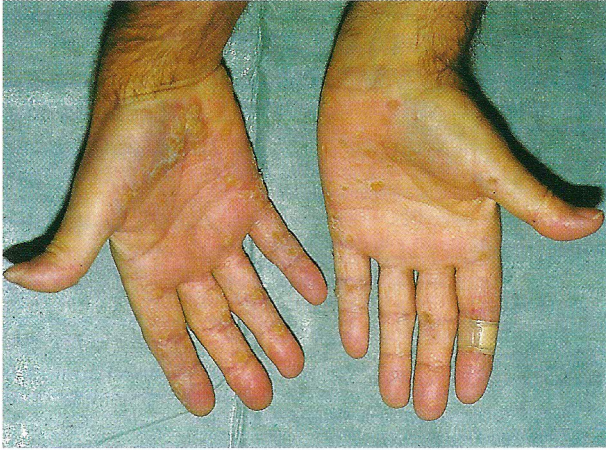


Fig. 1. Corn-like hyperkeratoses on the palms of the patient with hereditary palmoplantar papular keratoderma.

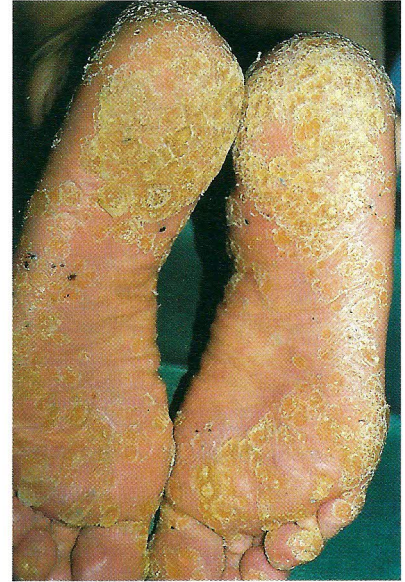

Fig. 2. Corn-like hyperkeratoses on the soles of the patient with hereditary palmoplantar papular keratoderma.

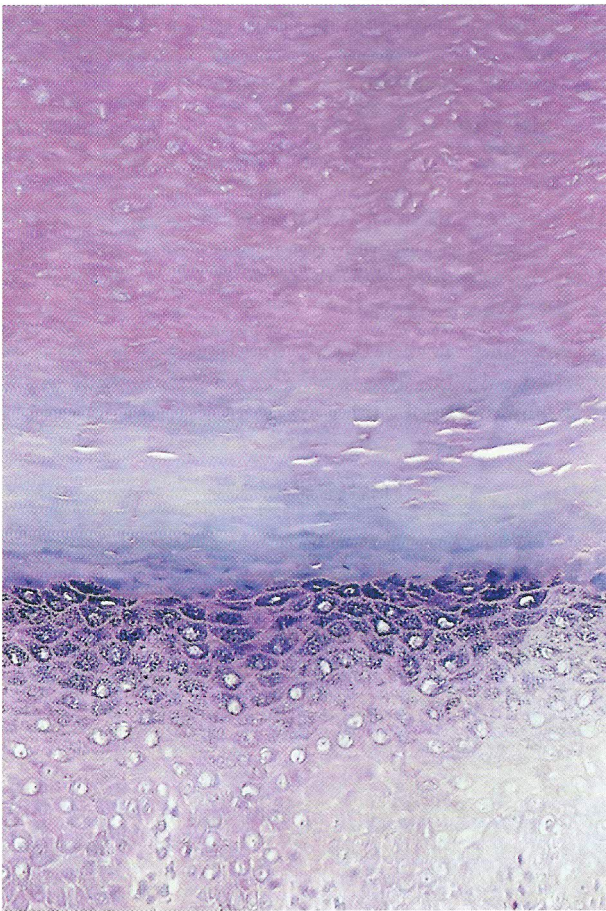


Fig. 3. Histopathology: unusually thickened and compact stratum corneum, hypergranulosis, and mild acanthosis. 250x

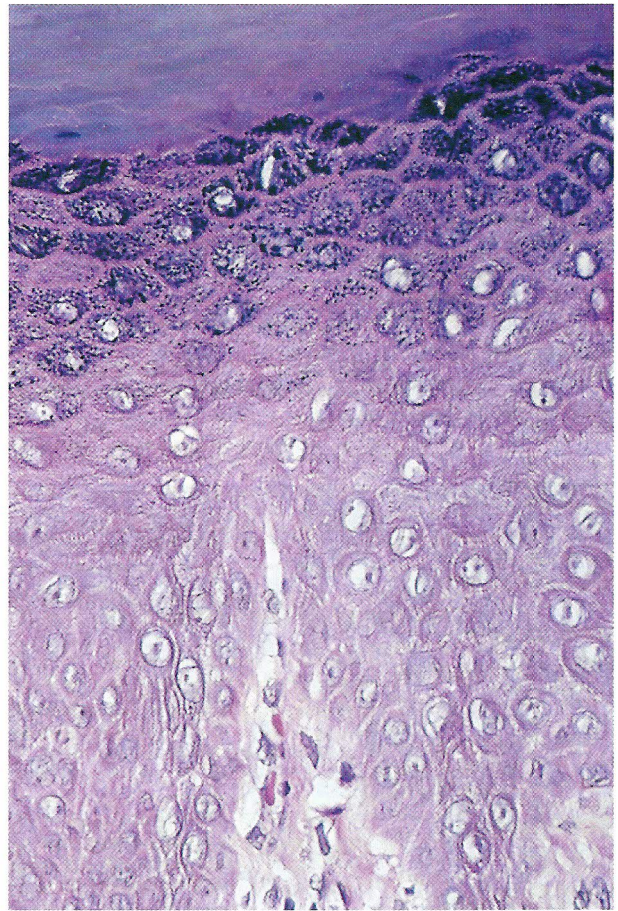


Fig. 4. Histopathology: hyperkeratosis, the granular layer is large, comprising up to 10 layers of cells, in the upper layers there are numerous large keratohyalin granules. 400 x

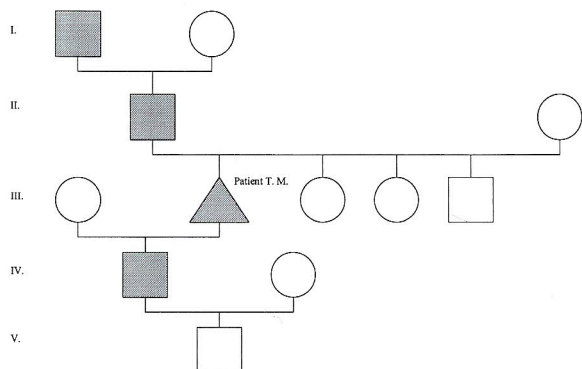


Fig. 5. The family tree of the patient T. M. with hereditary palmoplantar papular keratoderma

synonyms are used: keratosis palmoplantaris papulosa Buschke-Fischer-Brauer, keratoma hereditarium dissipatum palmare et plantare, keratoderma symmetrica maculosa disseminata palmaris et plantaris, disseminated clavus of the hands and feet (1). The disorder is transmitted in a regular autosomal-dominant mode (1). Sporadic cases have been also reported (9). This condition must be differentiated from the acquired forms. In both instances (hereditary and acquired forms) it may be linked to internal malignancies (10,11). Compared to other HPPKs, the disease appears later in life, usually at the age 15 - 30 years (1,9).

The disease is clinically manifested by a large number of isolated, corn-like, cone-shaped hyperkeratoses, symmetrically distributed on the palms and soles. Hyperkeratoses may be removed without

bleeding, leaving basin-shaped indentations (1). Associated abnormalities are uncommon (12,13).

A few cases of HPPK papulosa with concomitant disorders have been reported: cases of HPPK papulosa and superficial dystrophy of cornea, HPPK papulosa and lipomas (13).

Patients usually complain of painful sensations when walking, standing or doing manual work. There is no spontaneous remission (1).

CASE REPORT

A 68-year-old man, T. M. born in 1930, was examined by a dermatologist because of several hyperkeratoses of palms and soles. The lesions started at the age of 30 years.

Family history: similar changes on the palms and soles had also patient's father and grandfather; his son has similar symptoms. Two patient's sisters, one brother, a 25-year-old grandson, as well as one nephew are symptom-free (Figure 5).

Personal history: the patient was treated for pulmonary tuberculosis in 1958, a duodenal ulcer was detected in 1975 and three cysts of the left kidney in 1990. He survived an acute myocardial infarction in 1996; two times he suffered from pulmonary edema. In 1996, he was treated with radioactive iodine because of the hyperthyreosis.

Social and occupational history: the patient is married and has one son. He completed four years of primary school and worked as a coal-miner. Due

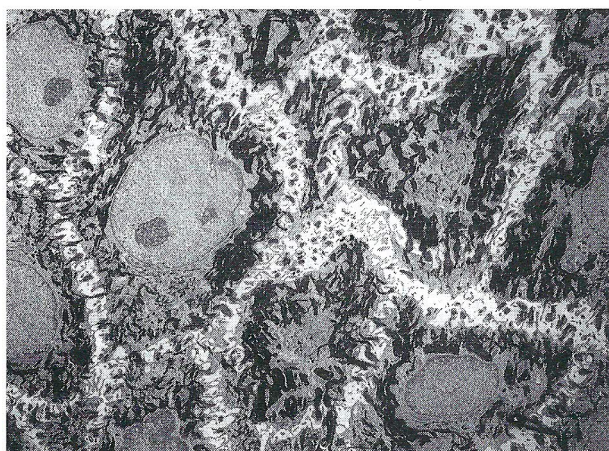


Figure 6. Electron microscopy: keratinocytes of the granular layer display thick tonofilament bundles.

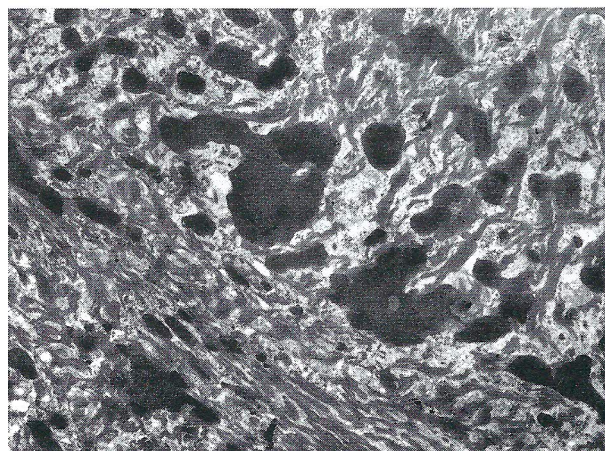


Figure 7. Electron microscopy: large keratohyalin granules in the granular cell layer.

to inconvenience caused by the hyperkeratosis, he managed to obtain the qualification as a radio-mechanic. He is now retired.

A dermatological inspection revealed a large number of isolated hyperkeratoses on the palms and soles. Corn-like changes were symmetrically distributed on the palms and soles as well as on flexural aspects of fingers and toes (Figures 1 and 2). A mild hyperkeratosis was expressed on the both elbows; the knees were free of symptoms.

Histopathology: The horny layer was unusually thickened and compact, the number of sweat glands' ducts was increased. The granular layer was large comprising up to 10 layers. There was a mild acanthosis of the Malpighian layer, dermoepidermal junction was normal. In the papillary layer there was an increased number of slightly dilated vessels, some of them filled up with erythrocytes (Figure 3). With higher power numerous large, irregularly shaped keratohyaline granules were seen in the upper layers of stratum granulosum (Figure 4).

Electron microscopy demonstrated hyperkeratosis, hypergranulosis, and acanthosis of the epidermis. Focally, the keratinocytes in the spinous and granular layers contained thick bundles of tonofilaments. Very large keratohyaline granules were found in the granular layer. The ultrastructure of the dermis and of the dermoepidermal junction was normal (Figures 6 and 7).

Therapy: Keratolytic ointments were applied topically. Systemic retinoids were not recommended, due to

the presence of mentioned internal symptoms.

DISCUSSION

The therapy of HPPK papulosa is symptomatic; keratolytic ointments are mostly used. The effect of systemic retinoids may differ according to Christiansen: out of nine patients treated with etretinate 0,5 mg/kg/day, in three the results were good, in four moderate, while in two no effect was observed (14).

Epidemiological data on HPPK papulosa are scarce and inconsistent (12). In Slovenia, twelve cases in four families were detected until now, and five of them were examined (15). In an extensive population study in Croatia a prevalence of HPPK papulosa of 1.17 per 100.000 inhabitants was reported (12).

CONCLUSION

A patient with keratosis palmoplantaris papulosa, which is rather rare form of HPPK, is presented. Including the presently reported four cases, altogether 16 cases of this disorder have been detected in Slovenia. No relationship between previous cases and presented family could be established up to now.

ACKNOWLEDGEMENT

The preparation of the manuscript was supported by the Slovenian Ministry of Science and Technology; Grant No J3-9105.

REFERENCES

1. Braun-Falco O, Plewig G, Wolff HH. *Dermatologie und Venerologie*. Berlin: Springer Verlag, 1996; 686.
2. Küster W, Becker A. Indication for the Identity of Palmoplantar Keratoderma Type Unna-Thost with Type Vörner. *Acta Derm Venereol (Stockh)* 1992; 72: 120-2.
3. Hamm H, Happle R, Butterfass T, Traupe H. Epidermolytic Palmoplantar Keratoderma of Vörner: Is It the Most Frequent Type of Hereditary Palmoplantar Keratoderma? *Dermatologica* 1988; 177: 138-45.
4. Kansky AA, Potočnik M, Kansky A. The Papillon-Lefevre syndrome. *Acta Dermatoven APA* 1997; 6: 60-4.
5. Kanskz A, Penko M, Milakić-Snoj Z. Pachyonychia congenital. *Acta Dermatoven APA* 1994; 3: 153-60.
6. Kansky A, Arzenšek J, Rode M, Strojjan J. Keratoderma palmoplantaris of the Unna-Thost Type in Slovenia. *Acta Derm Venereol (Stockh)* 1984; 64: 140-3.
7. Buschke A, Fischer W. Keratoderma maculosa disseminata symmetrica palmaris et plantaris. In: Neisser A, Jacobi E (Hrsg) *Ikonographia dermatologica*. Bd. 1. Urban & Schwarzenberg, Berlin, 1910; S 183-92.
8. Brauer A. Über eine besondere Form des hereditären Keratoms (*Keratoma dissipatum hereditarium palmare et plantare*). *Arch Dermatol* 1913; 114: 211-36.
9. Rook A, Wilkinson DS, Ebling FJG et al. *Textbook*

of *Dermatology*; vol 2. Oxford: Blackwell Scientific Publications, 1994; 1381.

10. Bennion SD, Patterson JW. *Keratosis punctata palmaris et plantaris and adenocarcinoma of the colon*. *J Am Acad Dermatol* 1984; 10: 587-91.

11. Fegueux S, Bilet S, Crickx B. *Hyperkeratoze palmo-plantarie filiforme et cancer recto-sigmoidien*. *Ann Dermatol* 1988; 115: 1145-6.

12. Stanimirović A, Kansky A, Basta-Juzbašić A, Skerlev M, Beck T. *Hereditary palmoplantar kerato-*

derma, type papulosa, in Croatia. *J Am Acad Dermatol* 1993; 29: 435-7.

13. Schnyder UW, Klunker W. *Erbliche Verhornungsstörungen der Haut*. In: Jadasson J: *Handbuch der Haut-und Geschlechtskrankheiten, Ergänzungswerk, Bd VII*. Berlin, Springer, 1966; 899-901.

14. Christiansen JV. *Keratoderma punctata hereditaria treated with etretinate (Tigason)*. *Acta Derm Venerol* 1983; 63: 181-2.

15. Franzot J, Kansky A. *Keratoderma palmoplantaris papulosa in Slovenia*. *Med Razgl* 1982; 21: 363-8.

AUTHORS' ADDRESSES

Metoda Košiček MD, Department Dermatology, Clinical Center, Zaloška 2, 1525 Ljubljana, Slovenia

Tatjana Perkovič MD, pathologist, Department of Pathology, Medical Faculty,
Korytkova 2, 1525 Ljubljana, Slovenia

Tomaž Lunder MD, MSc, dermatologist Department Dermatology, Clinical Center,
Zaloška 2, 1525 Ljubljana, Slovenia

Marta Penko MD, dermatologist, Chairman of Department Dermatology, same address

Aleksej Kansky MD, PhD, professor of dermatology, same address, corresponding author