

Psoriasis of the nails and scalp

C. Misciali, B.M. Piraccini and A. Tosti

S U M M A R Y

About 50% of patients with psoriasis present involvement of the nails and/or the scalp. Psoriasis limited exclusively to these regions is not rare. Koebner phenomenon can at least partially explain the localization of psoriasis in these areas, which are continuously exposed to traumas. Manual work and pedal biomechanics are responsible for repetitive micro traumas to the fingernails and the toenails, respectively, while brushing and combing cause traumas to the scalp.

Although the histological findings of nail and scalp psoriasis are very similar to those of psoriasis of the glabrous skin, the clinical manifestations are substantially different, reflecting the particular anatomy and physiology of these regions.

Scalp psoriasis

Clinically, localized erythematous and scaly papules or plaques of scalp psoriasis are similar to those of skin psoriasis. Early lesions are often confined to the occipital area. Fully developed lesions show masses of heaped scales and a solid cap, which extends just beyond the hair margin. Involvement of the whole scalp can occur (1, 2) (Fig. 1).

Psoriatic scalp scales are gray, firm and thicker than those of other body regions; these can sometimes detach from the scalp and lay around the hair shafts as tubes (pseudo hair-casts) (3).

Occasionally, scalp psoriasis is associated with itching (1, 2).

Psoriatic alopecias

Telogen effluvium can accompany scalp psoriasis; it usually improves when the disease is in remission (4, 5). Sometimes telogen effluvium is acute but more often it has a chronic course. Its pathogenesis could be explained by psoriatic inflammatory cells that elicit cytokines. This phenomenon interferes with the normal growth cycle causing earlier telogen formation. Altered

K E Y W O R D S

psoriasis,
scalp, nails,
clinic,
pathology

keratinization of the follicles and mechanic damage due to scales, which could stop the hair growth, may also play a role in the pathogenesis of telogen effluvium in scalp psoriasis (4). Scalp psoriasis may provoke scarring alopecia in rare cases. The hair density is drastically reduced in affected scalp areas producing a permanent alopecia (6, 7).

In patients with psoriatic alopecias we have observed the following histopathological findings:

Parakeratosis with micro-abscesses of neutrophils in the horny layer, absence of granular layer, psoriasiform epidermal hyperplasia, and papillomatosis. Horny plugs in some follicle infundibula are present. Sebaceous glands are atrophic or absent. Atrophic sebaceous glands resemble mantle-like structures (Fig. 2). A moderately dense lymphocytic superficial perivascular infiltrate, slight edema and dilated blood vessels within the papillary dermis and around the infundibulum and isthmus are detected.

In vertical sections, an increased rate of catagen follicles may be present. The histological findings of psoriatic scarring alopecia show a complete absence of follicular units, replaced by fibrosis. The epidermis is thin and no inflammatory infiltrates are observed (8).

Figure 2. Mantle-like structures (H&E, 120x)

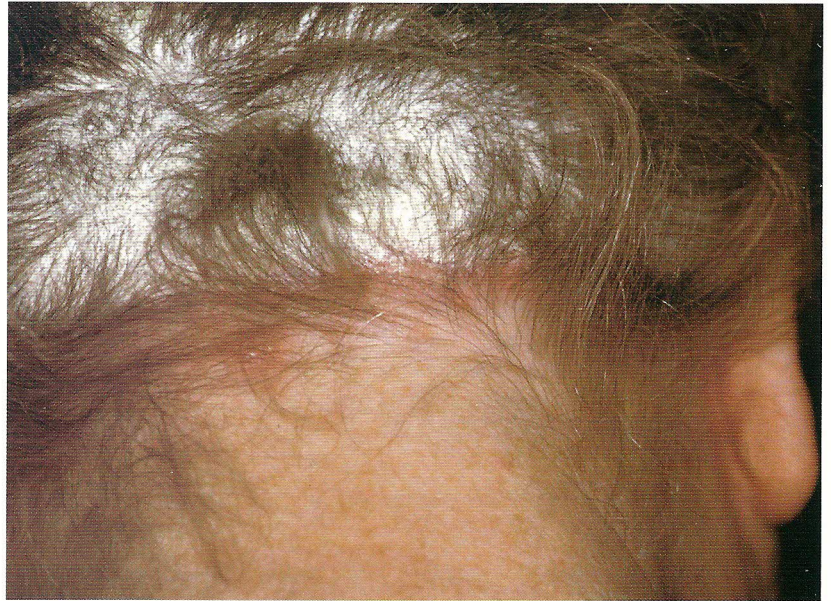
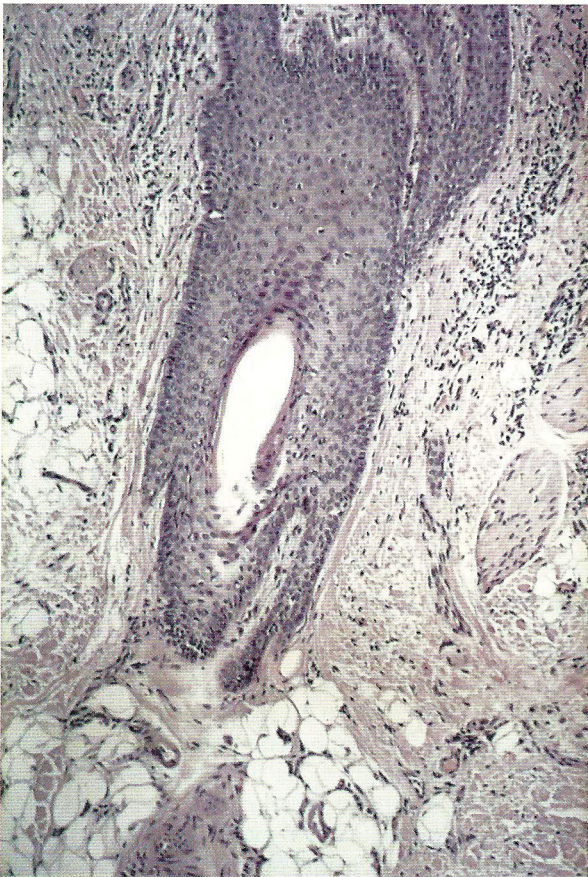
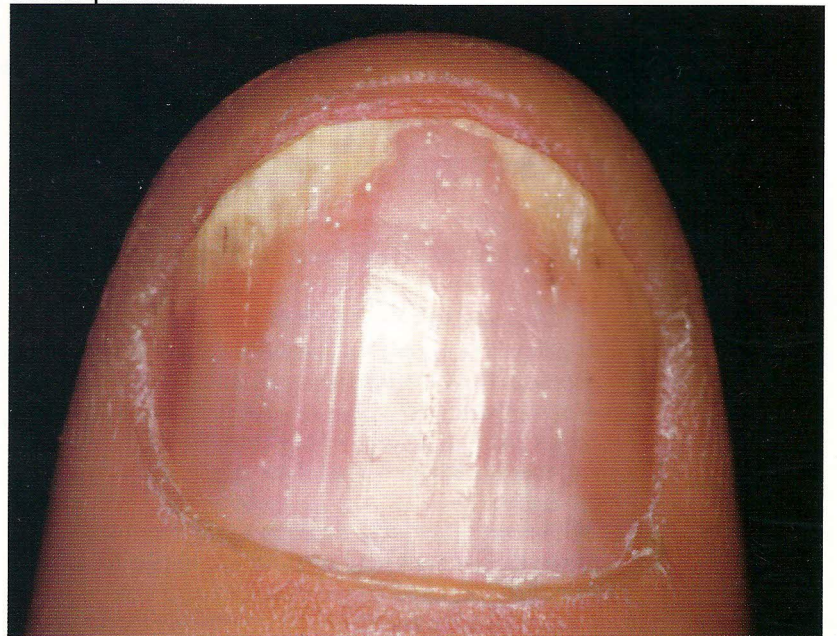Figure 1. Scalp psoriasis

Nail psoriasis

Signs of nail psoriasis depend on the localization of the disease in the nail unit (9, 10). A number of nail abnormalities often occur simultaneously due to involvement of different nail constituents in the same patients (9). Psoriasis affects fingernails more frequently than toenails. Psoriasis of all 20 nails is rare. The clinical manifestations of fingernail psoriasis are, in order of frequency: pitting, reddish oil (salmon) patches, ony-

Figure 3. Nail psoriasis: pitting, onycholysis and oil red patches



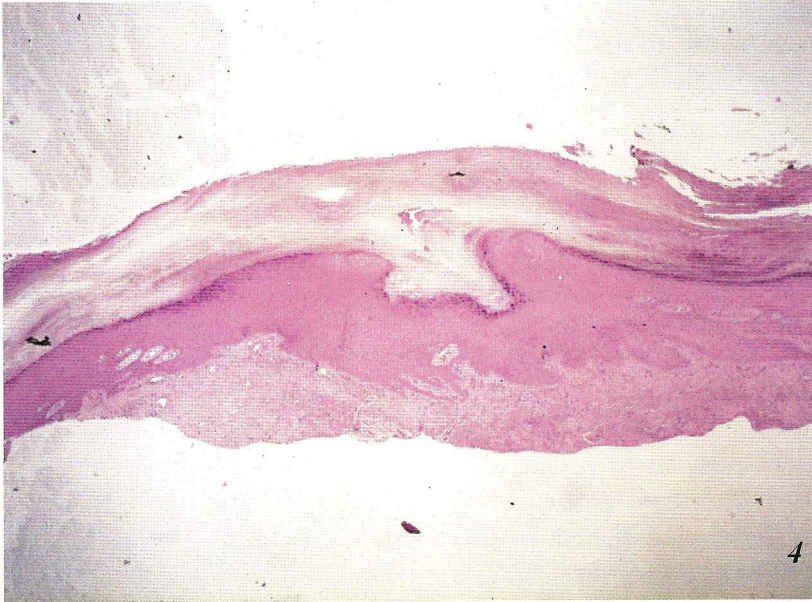


Figure 4. Cluster of parakeratotic cells and a pit in the distal nail plate (H&E, 35x).

cholysis (Fig. 3), subungual hyperkeratosis and splinter haemorrhages. Toenail psoriasis is usually characterized by monomorphic clinical signs and it consists of subungual hyperkeratosis and diffuse yellow-brown discoloration of the nail plate.

Pitting consists of punctate depressions (pits) of nail plate surface. Pits are deep, large and irregular and randomly distributed. Defective keratinization of the proximal nail matrix produces the persistence of clusters of parakeratotic cells within the upper layers of the nail plate. Histopathologically, pits represent desquamation of parakeratotic cells in the superficial nail (Fig. 4). Pits are rarely found in toenails. Differential diagnosis mostly includes pits of alopecia areata that are, however, symmetrically distributed in a regular pattern along the nail plate.

Salmon patches and *onycholysis* are due to involvement of the nail bed and are often associated (9, 10, 11).

Salmon patches are yellowish or salmon pink areas, irregular in size and shape visible through the transparent nail plate. This sign is typical of psoriasis.

Onycholysis represents the distal or lateral detachment of the nail plate from the nail bed. Histopathologically, it is characterized by parakeratosis of the nail bed horny layer (12). Onycholysis is whitish because of the penetration of air under the detached nail plate. In psoriasis, the onycholytic area is typically surrounded by an erythematous border.

Subungual hyperkeratosis describes the accumulation of parakeratotic cells under the distal portion of the nail plate and hyponychium. In fingernails, parakeratotic cells often lose their cohesion and are progressively eliminated resulting in the development of onycholysis. In toenails, hyperkeratosis is usually tightly adherent to the nail plate, which becomes hard, thick and lifted up. Nail abnormalities seen in psoriasis and onychomycosis may be indistinguishable since subungual hyperkeratosis, onycholysis and splinter haemorrhages are clinical signs of both these conditions. Dermatophytes or other fungi can colonize psoriatic nails. Therefore a positive culture does not rule out

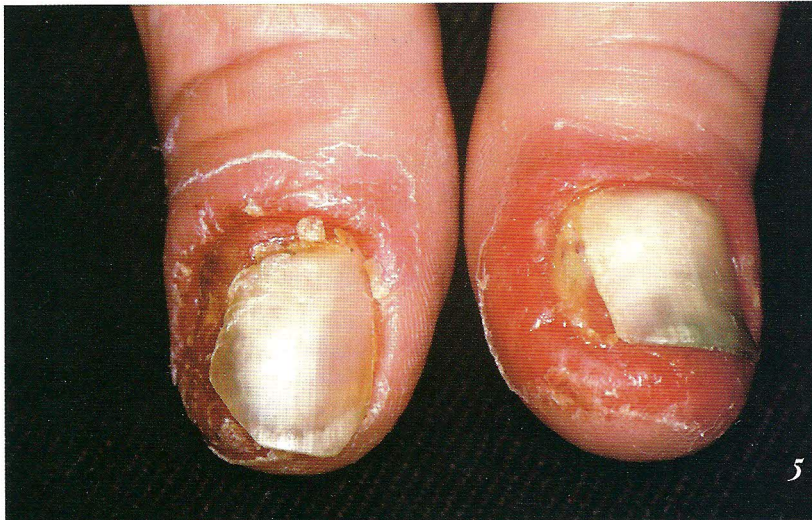

Figure 5. Pustular psoriasis.

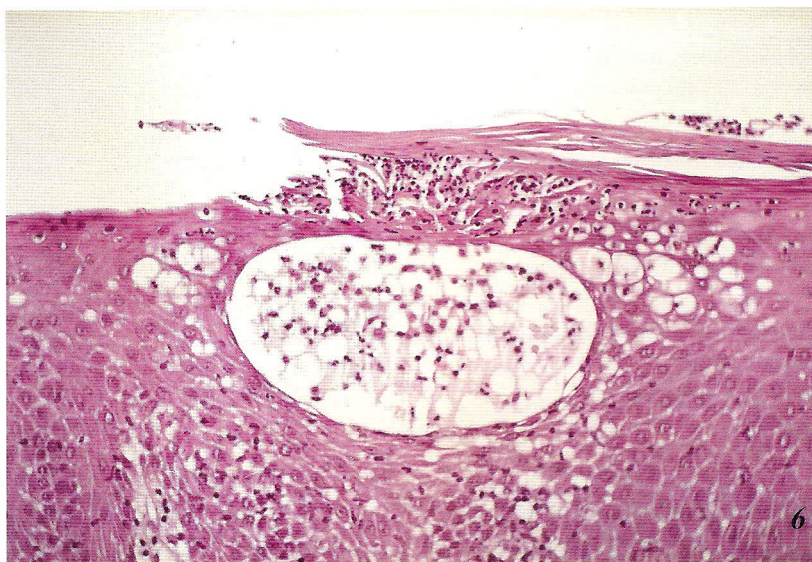


Figure 6. Pustula with massive edema and spongiosis in the nail bed (H&E, 120x).

psoriasis, which could promote growth of fungi into the nails (13).

Pustular psoriasis frequently affects the nail unit.

Nail involvement can occur in palmoplantar pustular psoriasis as well as in Hallopeau's acrodermatitis in which, usually, only one digit (most commonly a finger) is affected. In pustular psoriasis painful pustular lesions develop in the soft periungual tissues as well as in the nail bed and are associated with severe inflammation (Fig. 5) (14).

In histopathological sections, pustular psoriasis

shows pustules with massive edema, spongiosis of the nail bed (Fig. 6) and yellow brown scales and crust in the nail plate. Development of recurrent pustular lesions in the nail matrix area is not common and results in onychomadesis. Scarring of the involved nail matrix with partial or total loss of the nail plate is rare.

Longstanding lesions produce a definitive atrophy of the nail apparatus and periungual soft tissues (9, 11).

Nail psoriasis has an unpredictable course. It often gets worse during the summer. Stressful events may precipitate relapses. In most cases the disease is chronic and complete remissions are uncommon (9).

REFERENCES

1. Dawber R, De Berkerd PR. Diseases of the scalp and skin diseases involving the scalp. In: Dawber R. Diseases of the hair and scalp. Oxford. Blackwell Science. 1997: 494-527.
2. Orfanos CE, Frost PH. Seborrhoeic dermatitis, scalp psoriasis and hair. In: Orfanos CE, Happle R (eds). Hair and hair diseases. Berlin. Springer. 1990: 641-61.
3. Shuster S. Psoriatic alopecia: Br J Dermatol 1972; 87: 73-7.
4. Schoorl WJ, Van Baar HJ, Van de Kerkhof PCM. The hair root pattern in psoriasis of the scalp. Acta Derm Venereol (Stockh) 1992; 72: 141-2.
5. Runne U, Kroneisen-Wiersma P. Psoriatic alopecia: acute and chronic hair loss in 47 patients with scalp psoriasis. Dermatology 1992; 185: 82-7.
6. Wright AL, Messenger AG. Scarring alopecia in psoriasis. Acta Derm Venereol (Stockh) 1990; 70: 156-9.
7. Kretzschmar L, Bonsmann G, Metz D, Luger TA, Schwarz T. Scarring psoriatic alopecia. Hautarzt 1995; 46: 154-7.
8. Bardazzi F, Fanti PA, Orlandi C, Chieragato C, Misciali C. Psoriatic scarring alopecia. Observations in four patients. Int J Dermatol. 1999; in press.
9. Tosti A, Morelli R, Bardazzi F, Piraccini BM. Psoriasi ungueale. In: Dubertret L. Psoriasi. ISED; Brescia; 1993: 201-7.
10. Zaias N. Psoriasis of the nail. A clinical-pathological study. Arch Derm 1969; 99: 567-79.
11. Zaias N. Psoriasis of the nail. In: Zaias N. The nail in health and disease. MTP. Lancaster. England. 1980: 151-62.
12. Robbins TO, Kouskoukis CE, Ackerman AB. Onycholysis in psoriatic nails. Am J Dermatopathol 1983; 5: 39-41.
13. Gupta AK, Lynde CW, Jain HC, Sibbald RG, Elewski BE, Daniel CR 3rd, Wateel GN, Summerbell RC. A higher prevalence of onychomycosis in psoriatics compared with non-psoriatics: a multicentre study. Br J Dermatol 1997; 136: 786-9.
14. Burden AD, Kemmet D. The spectrum of nail involvement in palmoplantar pustulosis. Br J Dermatol 1996; 134: 1079-82.

AUTHORS' ADDRESSES

Cosimo Misciali, MD, Department of Dermatology, University of Bologna, Via Massarenti 1, 40138 Bologna, Italy
Bianca Maria Piraccini, MD, same address
Antonella Tosti, MD, same address