

Dysplasia ectodermalis hypohidrotica

D. Jovanović, S. Vojinović-Jovanović, M. Paravina, M. Stanojević,
M. Ljubenović and M. Slavković-Jovanović

SUMMARY

Hypohidrotic ectodermal dysplasia is a rare, congenital disease. We present a child, 10-year-old boy, with dysplasia ectodermalis hypohidrotica. In addition to the characteristic physical appearance, clinical features include total congenital alopecia, reduced sweating, ichthyosis, disturbed permanent dentition, marked mental retardation, and epilepsy. The son of the child's aunt (mother's sister) has the same skin lesions, without epilepsy, the father's brother suffers from epilepsy.

Introduction

The term hypohidrotic ectodermal dysplasia connotes a heterogeneous group of genodermatoses. It includes diseases and syndromes of variable expression, bearing characteristics of ectodermal epidermal abnormalities and at least one of dermal adnexes. Symptoms as a result of involvement of other organs (asthma, atopic dermatitis, bone changes, CNS and intellectual disturbances etc.) are often present (1,2,3,4,5,6,7). Among other syndromes of this group, two are most often described: dysplasia ectodermalis hypohidrotica et anhidrotica and dysplasia ectodermalis hidrotica.

Hypohidrotic and anhidrotic ectodermal dysplasia is an autosomal-recessive or X-linked hereditary syndrome. As a rule, patients are of male sex. The disease was first described in 1900 by Jacquet, and Touraine who pointed out ectodermal characteristics in 1937 (1). Patients have a characteristic appearance from their early childhood (although some changes may develop later):

a large forehead with pronounced frontal prominences, a saddle-shaped nose, and big ears. Sweating is poor or totally absent. Both milk- and permanent dentition are altered; teeth sometimes are completely absent. The hair is sparse, teared or absent. Nails may be dystrophic (1,2,4,5). Patients are often inclined to respiratory infections (1).

Hidrotic ectodermal dysplasia is of autosomal-dominant inheritance. There are no sweating disturbances. Diffuse alopecia and dystrophic nail changes are often present (1,4,5).

Case report

Our patient is a 10-year-old boy (born in 1988.), a second child by birth. Pregnancy and delivery were normal, in term and without complications. His parents and older sister are healthy. The aunt's (mother's sister)

KEY WORDS

ectodermal dysplasia, alopecia, disturbed sweating, ichthyosis, epilepsy

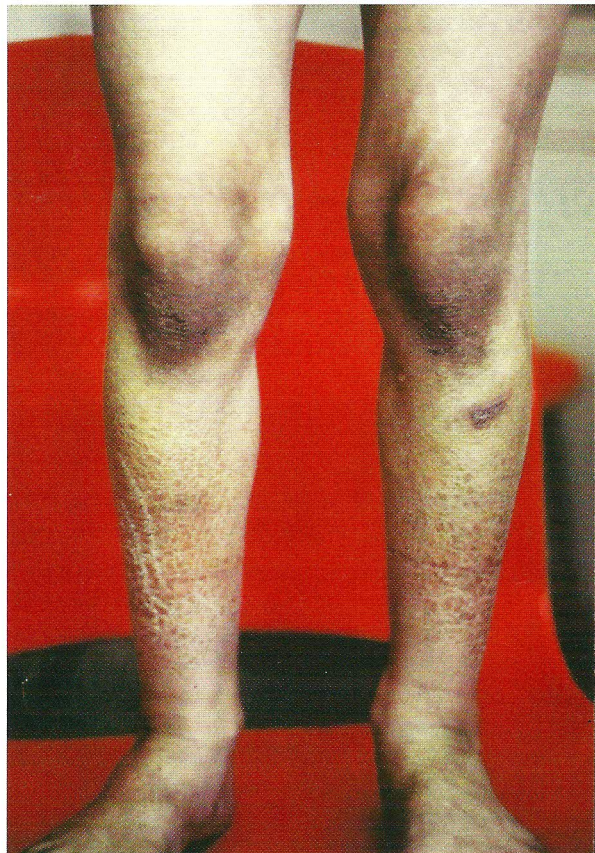

Figure 1. The entire skin is covered with grayish ichthyosiform scales, which are most intense on the extensor sites of the extremities.

son has the same changes, without epilepsy. The father's brother suffers from epilepsy.

The child's psychomotor development was generally normal. Milk-dentition was normal, but later permanent maxillary canines failed to grow. Ever since birth, the child is hairless, eyelashes and eyebrows are absent. In the third month of life a surgical correction of inguinal hernias was done. In the seventh month of life, the child had a strong allergic reaction to cheese and eggs and since then periodical redness of the skin with itch appeared. During the first year of life, the child was twice hospitalized because of bronchitis. In the thirteenth month of life he had the first convulsion attack, followed by the loss of consciousness. After that, he was several times hospitalized because of the same problems, and is still under permanent antiepileptic therapy and control by the pediatric neuropsychiatrist. During the third year of life, the skin became dry and scaly.

Sweating is poor, expressed only on the face and neck.

The child attends a special school because of a marked mental retardation. He is often nervous and excited. Physically, the child resembles his mother very much.

The patient's appearance is characteristic: large forehead with pronounced frontal tubers, saddle nose,

big ears (Figure 1). The entire skin is dry, covered with grayish ichthyosiform scales, which are more intensive on extensor sides of the extremities and on the scalp (Figures 1 and 2). On the skin of the dorsal hand, as well as on the skin on the fingers and knees, follicular horn plugs are expressed. The skin of the palms and soles is diffusely thickened. On the scalp, eyebrows, and other areas of the body the hairs are totally absent. The eyelashes are also missing. Some nail plates are thickened. Maxillary canine teeth are absent, other teeth are normal. The symptoms of photophobia are present.

General pediatric and ophthalmologic findings are within normal values. Neuropsychiatric status: epilepsy with pathological EEG findings and mental retardation. Therapy includes Phenobarbiton and Carbamazepine tablets with regular controls.

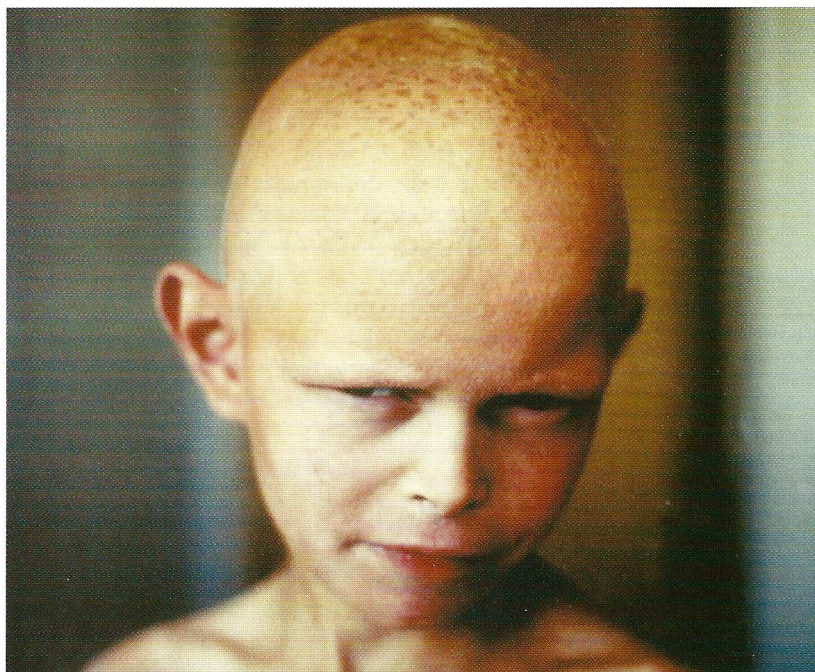
Laboratory findings (red blood cells sedimentation rate, blood cells count, urine analysis, and serum levels of urea, sugar, transaminases, electrolytes and liver function tests) are within physiological ranges. Syphilis serology is negative.

The child's mother refused biopsy of the skin, afraid of provoking an epileptic attack. Due to technical reasons, karyogram was not made.

Discussion

Clinical characteristics of the described patient pointed to hypohidrotic ectodermal dysplasia. Congenital diffuse atrichia is one of a numerous congenital cuta-

Figure 2. The hairs of the scalp, eyebrows and eyelashes are totally absent.



neous and somatic disturbances (5,8, 9,10,11). Aplasia or deficient hair follicles may be an epiphenomenon of different syndromes of ectodermal abnormalities (3) and trichotilodystrophia (10,11).

Ichthyosis, diffuse keratosis of the palms and the soles, photophobia without other pathological changes of the eyes, neurological disturbances with epilepsy are symptoms of the syndrome of ectodermal dysplasia. Possible similar findings in some disturbances associated with keratosis spinulosa decalvans, ichthyosis follicularis and similar diseases, must be considered for a possible differential diagnosis (12,13,14).

Patients with hypohidrotic and anhidrotic ectodermal dysplasia are rarely seen. They are found in families carrying a pathological gene (X-linked or autosomal-recessive inheritance). Our patient has a close relative in mother's family (the son of his mother's sister) with the same changes, but without epilepsy. We have seen this other patient once, but as he lives in another town he didn't come to scheduled controls for detail examinations. The mothers of both children are pheno-

typically very similar (they are sisters), and children physically resemble their mothers very much.

Therapeutic possibilities are of little help in patients with hypohidrotic and anhidrotic ectodermal dysplasia. Skin lesions are permanent. Life prognosis is not bad.

Disturbed thermoregulation as a possible reason for fainting spells is excluded in our patient. Neurological examination led to the diagnosis of epilepsy, mostly of grand mal type. There is also a genetic predisposition for epilepsy in our patient, since his father's brother suffers from this disease.

An important prognostic aspect of the disease is its possible occurrence in male descendants, while women are asymptomatic carriers of the pathological gene. Because of that, genetical consultations may help to prevent this disease.

Patients with hypohidrotic and anhidrotic ectodermal dysplasia need permanent dermatological monitoring and control, with a permanent, mostly symptomatic, treatment, as well as a close cooperation with other medical specialists.

REFERENCES

1. Andreev V, Zlatkov N. Dysplasio ectodermalis anhidrotica. Nasledstveni i vrodni bolesti i sindromi v dermatologijata. Medicina i fizikultura, Moskva, 1977; 114.
2. Bazex A, Dupre A, Christal B. Dysplasio congenitale ectodermique. Encycl Med Chir Dermatologie, Paris, 1967; 11, 12640 A 10, 3.
3. Dupre A, Viraben R. Syndromes complex avec dysplasie pilaris. In: Saurat JH, Grosshans E, Langier P, Lachapelle JM eds. Dermatologie et venereologie, Masson, Paris, 1990; 621-3.
4. Harper J. Ectodermal dysplasias in: Champion RH, Burton JL, Ebling FJG eds. Rook/Wilkinson/Ebling Textbook of Dermatology, Blackwell Scientific Publications, London, 1992; 334.
5. Koloustin VM, Kurban AK. Genetic Diseases of the Skin. Springer-Verlag, Berlin, New York, 1979.
6. Martinović GN. Promene na adneksima kože u sklopu ektodermalnih displazija. Acta Medica Medianae 1998; 1:79-83.
7. Lambert D, Nivelon-Chevalier A, Nivelon IJ, Chapus LJ. Dysplasio ectodermalis anhidrotica. Ann Derm Venereol 1977; 104:298-303.
8. Ančevski A. Alopecii i drugi bolesti na kosata. Jugoreklam, Skopje, 1995.
9. Beurey J, Jeandidier P. Alopecies. Alopecies congenitales. Encycl Med Chir Dermatologie, Paris, 1969; 9, 12855 A 10, 2.
10. Guilaine J. Keratosis follicularis spinulosa decalvans in: Saurat JH, Grosshans E, Langier P, Lachapelle JM. eds. Dermatologie et venereologie, Masson, Paris, 1990; 229-30.
11. Schnyder KW. Les ichtyoses hereditaires. In: Saurat JH, Grosshans E, Langier P, Lachapelle JM eds. Dermatologie et venereologie, Masson, Paris, 1990; 207-14.
12. Touraine A. L'heredite en medecine. Masson, Paris, 1955.
13. Lepine J. Keratosis pilaires. Encycl Med Chir Dermatologie, Paris, 1970; 2, 12370 A 30, 3-4.
14. Eramo LR, Esterly NB, Zieserl EJ et al. Ichthyosis follicularis with alopecia and photophobia. Arch Dermatol 1985; 121: 1167-74.

A U T H O R S ' A D D R E S S E S

Dragan Jovanović, MD, MSc, teaching assistant, Clinic for skin and venereal diseases, Clinical Center Niš B.Tasković, G48, 18000 Niš Yugoslavia, Medical Faculty, University of Niš, Niš, Yugoslavia.
Snežana Vojinović-Jovanović, MD, PhD, professor and chairman, same address
Mirjana Paravina, MD, PhD, professor, same address
Milenko Stanojević, MD, PhD, associate professor, same address
Milanka Ljubenić, MD, same address
Maja Slavković Jovanović, MD, Clinic for pediatry, Clinical Center Niš B.Tasković, G48, 18000 Niš, Yugoslavia