

## APOCRINE EPITHELIUM WITHIN A TRICHILEMMAL CYST

L. K. Bickley, R. A. Schwartz and W. C. Lambert

### SUMMARY

The trichilemmal cyst, or pilar cyst, is typically lined by an epithelium that keratinizes in the manner of the outer root sheath of the hair follicle. Occasionally, aberrant histology may be present in the cyst wall. We present a trichilemmal cyst, the wall of which shows continuity with apocrine epithelium. This finding, which to our knowledge has not previously been reported, may represent an embryonic remnant.

### KEY WORDS

*trichilemmal cyst, pilar cyst, embryonic remnant, apocrine remnant, combined cyst, skin neoplasm*

---

The trichilemmal cyst, or pilar cyst, is a common benign cyst that usually develops on the scalp (1). Histopathologically, it exhibits keratinization typically seen in the outer root sheath of the hair follicle at the level of the follicular isthmus. At times, careful examination of a cyst wall can reveal aberrant histologic structures co-existing with the cyst. We report the occurrence of apocrine epithelium in continuity with the epithelium of a trichilemmal cyst.

### CASE REPORT

A 42-year-old white man presented to the Dermatology Clinic at the New Jersey Medical School, complaining of a solitary scalp nodule of several years duration. The lesion had slowly enlarged, but was otherwise asymptomatic. The patient had previously

undergone excision of lipomas on his chest and buttock. There was no prior personal or family history of cysts. The patient was in good health.

On physical examination, there was a firm, slightly mobile, non-tender subcutaneous nodule on the mid-frontal scalp, which measured approximately 8 millimeters in diameter. No punctum was evident. The lesion was felt to represent a pilar cyst and surgical excision was performed.

### HISTOPATHOLOGY

Microscopic evaluation revealed a dermal cyst with no identifiable epidermal connection. The majority of the cyst wall was composed of stratified squamous epithelium, which had a peripheral layer of germinative cells and lacked a granular layer. The lumen of the cyst was filled with compact, laminated, eosinophilic

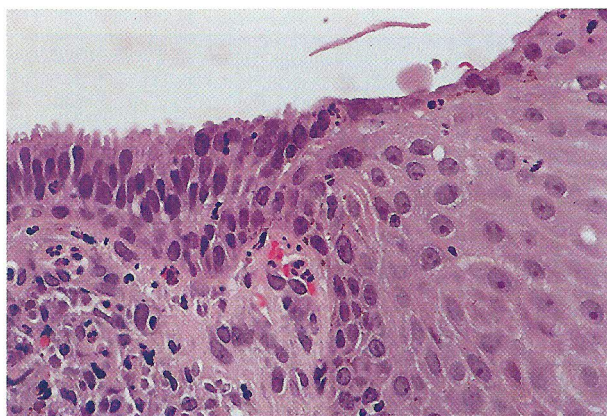


Fig. 1. Apocrine epithelium within a trichilemmal cyst. The area of abrupt transition of stratified epithelium to apocrine epithelium is shown. The columnar cells exhibit a characteristic decapitation secretion.

material that closely apposed the lining epithelium. In one area, the stratified epithelium demonstrated an abrupt transition to apocrine epithelium. This apocrine epithelium was composed of a single layer of columnar cells exhibiting characteristic decapitation secretion.

## DISCUSSION

Cutaneous cysts, particularly the epidermal and trichilemmal varieties, are common lesions that are routinely submitted for histopathologic examination. Each is composed of a characteristic epithelium and often distinct luminal contents that enable the pathologist to readily render a diagnosis. However, aberrant histologic structures are at times found in the walls of common cysts, the presence of which may suggest a common histogenesis.

The combined trichilemmal and epidermal cyst has been described by Brownstein, who reported seven examples of cysts in which the upper portion

showed epidermoid keratinization, while the inferior portion showed trichilemmal keratinization (2). Such hybrid cysts support the contention that epidermal and trichilemmal cysts are both derived from the follicle, with the epidermal cyst related to the follicular infundibulum and the trichilemmal cyst related to the isthmus. Similar hybrid cysts have also been described on the scrotum (3).

Apocrine glands in the adult are located primarily in their axillae and the perineum. However, during embryogenesis, apocrine anlagen are present on the scalp and subsequently resorbed (4). Since apocrine glands normally drain into hair follicles, it is possible that a benign tumor of the follicle such as a trichilemmal cyst could show residual apocrine epithelium, if the cyst formed near the site where the persistent duct of the apocrine gland joined the follicle. The case we present demonstrates this, showing an abrupt change from stratified squamous epithelium to a columnar layer with decapitation secretion. To our knowledge, this is the first reported example of this finding.

The occurrence of cysts composed of diverse but related histologic elements may be more common than is generally appreciated, since recognition requires careful examination of the entire cyst wall. Apocrine cystic neoplasms are not rare; some have unusual features (4-8). The association of pilomatricoma with both epidermoid and trichilemmal cysts has been described previously (9-11). The former represents the co-occurrence of differentiation characteristic of two nonadjacent areas of the follicle. Other rare findings in epidermoid and trichilemmal cysts include bowenoid papulosis (12), fatty metaplasia (13), Bowen's disease (14), and squamous cell carcinoma (15). It is important that, on one hand, such aberrant changes not lead to an incorrect diagnosis, and, on the other, that cyst walls be scanned for changes, such as squamous cell carcinoma, that must be separately diagnosed and are of prognostic importance.

## REFERENCES

1. Leppard BJ, Sanderson KV. The natural history of trichilemmal cysts. *Br J Dermatol* 1976; 94: 379-90.
2. Brownstein MW. Hybrid cyst: a combined epidermoid and trichilemmal cyst. *J Am Acad Dermatol* 1983; 9: 872-5.
3. Song DH, Lee KH, Kang WH: Idiopathic calcinosis of the scrotum: histopathologic observations of fifty-one nodules. *J Am Acad Dermatol* 1988; 19:1095-101.
4. Kruse TV, Khan MA, Hassan MO. Multiple apocrine cystadenomas. *Br J Dermatol* 1979; 100: 675-81.
5. Bickley LK, Goldberg DJ, Imaeda S, Lambert WG, Schwartz RA: Treatment of multiple apocrine hidrocystomas with the carbon dioxide (CO<sub>2</sub>) laser. *J Dermatol Surg Oncol* 1989; 15: 599-602.

6. Lambert WC, Wiener BD, Schwartz RA, Quillen CG, Giampapa VC: The giant apocrine hidrocystoma. *J Surg Oncol* 1984; 27: 146-51.
7. Schwartz RA, Rojas-Gorona R, Lambert WC: The polymorphic apocrine nevus. A study including carcinoembryonic antigen staining. *J Surg Oncol* 1984; 26: 183-6.
8. Lambert WG, Brodtkin RH, Schwartz RA: Apocrine adenocarcinoma developing within a longstanding apocrine hidrocystoma. *Proc Annual Meeting of the American Society of Dermatopathology*, 1986, pp 111.
9. Moss RL, Murray DW. Epidermal inclusion cyst with pilomatricoma. *J Assoc Military Dermatol* 1985; 11 (2): 52-3.
10. Benharroch D, Sacks MI. Pilomatricoma associated with epidermoid cyst. *J Cutan Pathol* 1989; 16: 40-3.
11. Chuo NI, Kimball GP, Craft JL, Wang WJ, Ghong GS, Albert DM. Calcifying epithelioma: a clinicopathological analysis of 67 cases with ultrastructural study of 2 cases. *Internat Ophthalmol Glin* 1982; 22 (I): 63-86.
12. Masessa JM, Schwartz RA, Lambert WC. Bowenoid papulosis in a penile epidermal inclusion cyst. *Br J Dermatol* 1987; 116: 237-9.
13. Fulk CS. Trichilemmal cyst of the buttock. *J Assoc Military Dermatol* 1981; 7 (2): 46-7.
14. Shelley WB, Wood MG. Occult Bowen's disease in keratinous cysts. *Br J Dermatol* 1981; 105:105-8.
15. Davidson TM, Bone RC, Keissling PJ. Epidermoid carcinoma arising from within an epidermoid inclusion cyst. *Ann Otol Rhinol Laryngol* 1976; 85: 417-8.

#### AUTHORS' ADDRESSES

Lynn K Bickley MD, Department of Dermatology, New Jersey Medical School,  
185 South Orange Avenue, Newark NJ 07103 2714  
Robert A. Schwartz MD, MPH, Professor and Head Dermatology, same address  
William C. Lambert MD, PhD, Professor and Associate Head Dermatology,  
Chief Dermatopathology, same address