

LICHEN AUREUS

V. Dragoš, R. Popovič, M. Berčič and J. Miljkovič

ABSTRACT

In the course of two years, an eight year-old girl developed an eruption corresponding macroscopically and microscopically to lichen aureus. This entity is a variant of the pigmented purpuras, and only occurs very rarely in childhood. It generally causes no complaints, but is rather chronic in course and resistant to therapy. The etiology remains unknown.

KEY WORDS

lichen aureus, occurrence in childhood

Lichen aureus may be regarded as an uncommon variant of pigmented purpuric eruption, distinguished by its chronicity, its limitation to one or two sites, and lichenoid histologic features (1). Lichen aureus is a rarely reported dermatosis, generally occurring in otherwise healthy young adults. A literature search disclosed only few reports of this eruption in children (2,3).

It is characterized clinically by scattered, close-set lichenoid papules. They are localized in a circumscribed area, with a predilection for one of the extremities, and usually unilateral in distribution. The color of the lesions varies from golden (aureus) to a rusty brown hue (purpuricus). The histology is characterized by a band-like, (predominantly) mainly mononuclear infiltrate in the upper part of the dermis, separated from the epidermis by a narrow zone of normal tissue in most regions (4).

CASE REPORT

In April 1993, an 8 year-old girl developed scattered pigmented patches on the extensor region of her left calf. Her parents interpreted these as bruises, since she had been roller-skating often at the time. She was nearly asymptomatic only occasionally complaining of slight pruritus. Over the next few

months, new satellite lesions developed in a linear pattern on the distal portion of her left calf. The patient's medical and family history were noncontributory (unremarkable), and medication at the time of onset was denied.

On first examination in February 1994, a few patches were seen, varying in size from 1 to 3 cm in diameter. The eruption consisted of flattened, purple-red papules with slight scaling (Fig. 1). Under diascopy, the patches appeared reddish brown.

On examination in September of 1994, the patches had changed to a rusty-golden color, the lesions otherwise remaining unchanged.

In April of 1994, a skin biopsy was performed, revealing a normal epidermis and a band-like infiltrate in the upper dermis, consisting mainly of lymphocytes as well as many extravasated erythrocytes. The vessels were dilated (Fig. 2 and 3). Direct immunofluorescence disclosed deposits of IgM, C3, and fibrin/fibrinogen in the vessel walls. IgM and C3 deposits were also found in the epidermo-dermal zone. No immunofluorescence was seen corresponding to IgA, IgG, C1q, or C4. The observed pattern showed no specificity.

The routine laboratory tests were within normal limits, except for detecting once staphylococcus aureus in the pharynx by a swab.

DISCUSSION

Lichen aureus, characterized by persistent, grouped lichenoid papules having a distinctive rust, copper, or burnt-orange color, is classified among the pigmented purpuric eruptions (4).

Whereas the other variants, such as Shamberg's progressive pigmented purpuric dermatosis and Majocchi's purpura annularis teleangiectoides are now grouped together, several authors believe that lichen aureus is sufficiently distinctive both clinically and histologically, to be recognized as a separate entity (5,6).

Lichen aureus is a rare dermatosis; the lesions are generally localized in a circumscribed area, usually on one extremity, and unilaterally there (1). However, other sites (trunk, fingers, hands) may be involved (5).

The majority of cases occur in young adults (1,6,7,8), while a review of the literature yielded only two reports of lichen aureus in children (2,3). The condition may initially be interpreted as bruising, without an obvious trauma (5,6). The eruptions generally cause no complaints, and pruritus, if present, is mild. Lichen aureus is a very chronic and therapy resistant disease, lasting for years. A relationship to other diseases or drug use (use of medications) has never been proven (1). After progression over a short period of time, the lesions become stationary. Topical steroids may reduce the inflammation, but do not alter the color of the lesions (6).

A review of the histological changes suggests that

they often overlap with those of other pigmented purpuric eruptions. The epidermis is usually unaffected, but atrophy and hyperkeratosis may be seen (6). A dense, band-like infiltrate composed of lymphocytes and histiocytes is present in the upper dermis and around the capillaries. Swollen endothelial cells and extravasated erythrocytes are also characteristic (4).

Direct immunofluorescence studies were only performed in few cases, and revealed no specificity. The absence of granular deposits along the BM basement membrane (BM) and in the walls of vessels indicates that immune complexes most probably do not play a role in the pathological process (1,8). The nature of the endothelial damage in lichen aureus has not yet been determined. Preliminary studies with specific endothelial cell markers do not suggest a pathological change in the vessels at the involved sites (5). Price et al (5) suggest further studies of blood vessels and their endothelial cells, as well as investigation of the infiltrate by immunohistochemical techniques in order to elucidate the pathogenesis of lichen aureus.

Both the clinical and histological findings in the reported patient correspond to the diagnosis of lichen aureus. To date, she is the youngest patient diagnosed with this disease in the region served by our hospital. Lichen aureus being a variant of the pigmented purpuras, its rare occurrence in children is surprising.

Nevertheless, it is an entity requiring consideration even in this age group.

REFERENCES

1. Verbung Van Der Zwan N, Manual HR. Lichen purpuricus. *Dermatologica* 1976; 152: 347-351
2. Pinol-Aquade J, Peyri Rey J, Quintana J, et al. Lichen aureus. *Med Cutan Iber Lat Am* 1974; 4: 263-266
3. Kahana M, Levy A, Schewach-Millet M, Trau H, Feinstein A. Lichen aureus occurring in childhood. *Int J Dermatol* 1985; 24: 666-667
4. Braun-Falco O, Plewig G, Wolff HH, Winkelmann RK. Hemorrhagic Disorders In: *Dermatology* 3rd ed Berlin, Heidelberg: Springer Verlag, 1991: 661
5. Price ML, Wilson Jones E, Calnan CD, Macdonald DM. Lichen aureus: A localized persistent form of pigmented purpuric dermatitis. *British Journal of Dermatology* 1985; 112: 307-314
6. Abramovits W, Landau JW, Lowe NY. A report of two patients with lichen aureus. *Arch Dermatol* 1980; 316: 1183-1184
7. Waisman M, Waisman M. Lichen aureus. *Arch Dermatol* 1976; 112: 696-697
8. Maciejewski W, Bandmann HJ, Klawiter M. Lichen purpuricus /Lichen aureus/ *Der Hautarzt* 1979; 30: 440-442

AUTHORS' ADDRESSES

Vlasta Dragoš MD, dermatologist, Dpt. Dermatology, Clinical Center, Zaloška 2, 61000 Ljubljana, Slovenia
Ranka Popovič MD, MSc, dermatologist, same address
Marija Berčič MD, PhD, dermatologist, Dpt. Dermatology,
General Hospital Maribor, Ljubljanska 5, 62000 Maribor, Slovenia
Jovan Miljkovič MD, same address

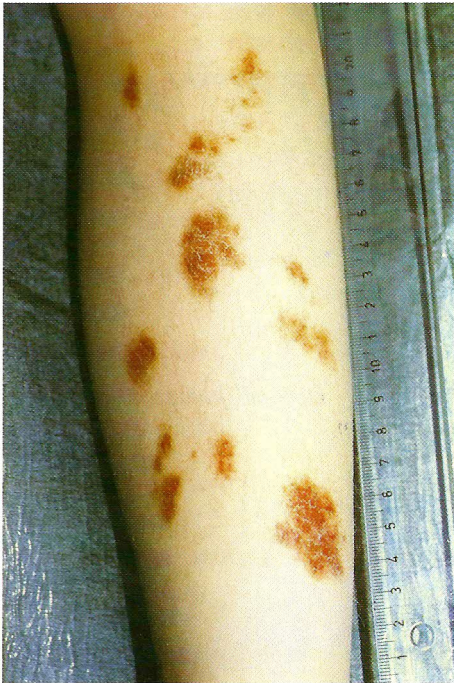

Figure 1. Flattened purple-red papules on the anterior aspect of the left leg.

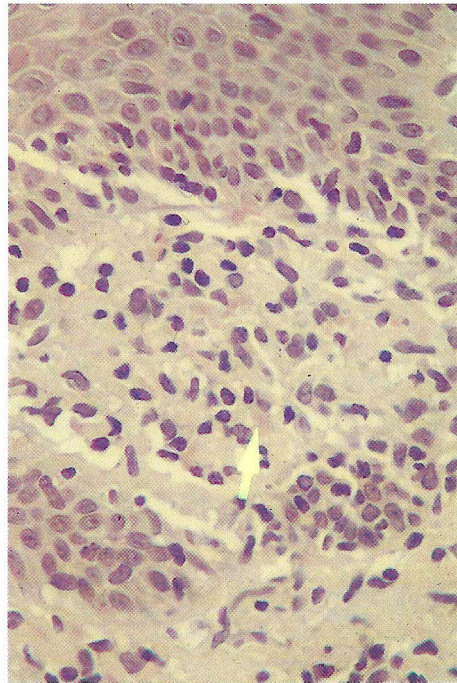


Figure 3. Higher magnification shows the erythrocytes in the lymphohistiocytic infiltrate (arrow). H&E 16 x 10.

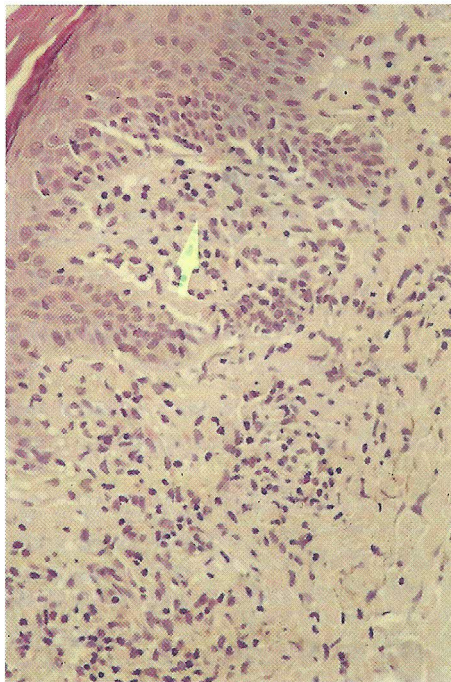


Figure 2. Histopathologic features. A slight acanthotic epidermis and a lichenoid lympho-histiocytic infiltrate containing extravasates. H&E 10 x 10.

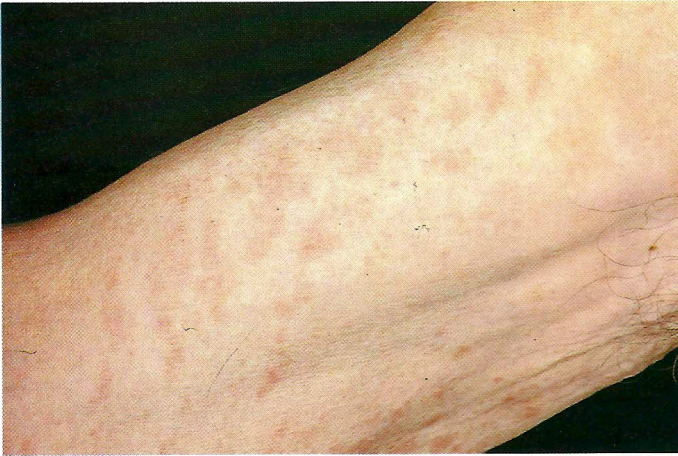

Figure 1. Digitate parapsoriasis on the right upper arm.

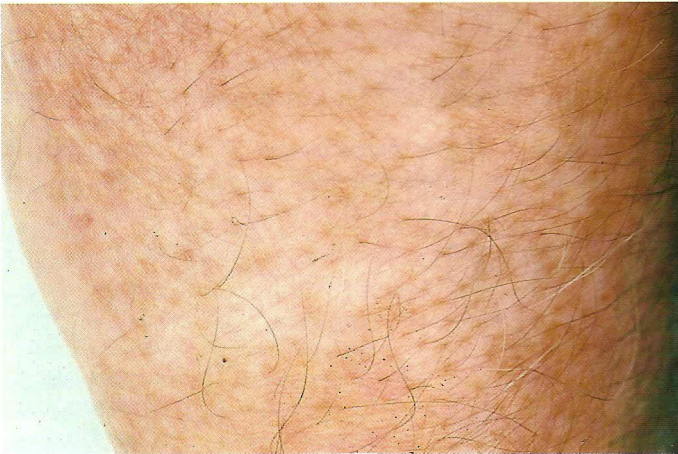

Figure 2. Vitiligo area on the left arm.

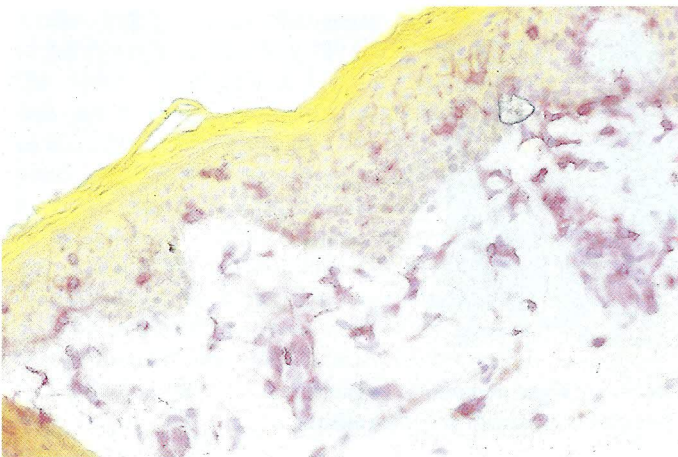


Figure 3. Multiple CD4+ lymphocytes perivascular and periadnexial with epidermotropism in a parapsoriatic lesion.