

PACHYONYCHIA CONGENITA

A. Kansky, M. Penko and Z. Milakić-Snoj

ABSTRACT

Pachyonychia congenita (PC) is a rare dermatosis belonging to the broad group of hereditary palmoplantar keratoses. Judging by the reports in the literature it seems to be rare in large populations but is not that much rare in South-Slav peoples. The main symptoms are a substantially thickened nail-plate of greyish-brown color and a rough surface, follicular hyperkeratosis of the face and extensor surfaces of the proximal parts of extremities and also elsewhere, insular hyperkeratosis of palms and soles with blisters appearing at hyperkeratotic areas especially in summer, leukokeratosis of oral mucosa as well as other less important symptoms. Although a number of disorders may share certain common symptoms, the most serious diagnostic problems present candidiasis and epidermolysis hereditaria dystrophica dominans.

The inheritance is assumed to be autosomal dominant, there are however certain observations which allow a somewhat different interpretation. These observations are reviewed in details. The true pathologic mechanism responsible for the disorder is not known. The methods for treating PC have been up to now rather, unsatisfactory.

To make this problem apparent a Slovenian family with PC is presented.

KEY WORDS

pachyonychia congenita, symptoms, incidence, genetics, micromorphology, treatment, presentation of a family

Synonyms

Pachyonychia congenita (PC), Jadassohn-Lewandowsky syndrome, polykeratosis congenita (Touraine), keratosis disseminata circumscripta, leukokeratosis linguae (1,2)

General data

Pachyonychia congenita (PC) is a rather rare form

of hereditary palmoplantar keratoderma (HPPK). The first documented observation was made in 1904 by Müller (3) which was followed by Wilson (4) and Jadassohn and Lewandowsky (5) in 1906. Since then more than 250 cases were reported in the literature. Certain reports include a larger number of cases e.g. Moldenhauer and Ernst (6) reviewed 93 cases and reported 6 newly detected, Puente mentioned 26 patients (7), Kumer and Loos 23 (8),

Su et al 12 (9), 14 cases were reported from Slovenia and 25 from Croatia (11).

Clinical symptoms

The main skin symptoms of PC are: an insular hyperkeratosis of palms and soles, a follicular hyperkeratosis primarily of the face and proximal parts of the extremities but also of other parts of the body, hyperhidrosis of palms and soles, periodical appearance of blisters especially during childhood, substantially thickened nail plates of brownish-grayish color and of a rough surface. Oral mucosa is usually also affected: on the tongue, buccal mucosa and sometimes also on the gingiva there are displayed smaller or larger areas of whitish hue (leukokeratosis) which should not be confounded with leukoplakia. If laryngeal mucosa is also involved a hoarseness results.

Other more rare symptoms are prenatal dentition, eye symptoms as cataract or dyskeratosis of cornea, as well as cicatricial alopecia.

The affected nails may already be observed during the first months of life (9,12) but they may appear later (9,10,13,14), Paller described 5 cases in which the disfigured nails became manifest during the second and third decade of life (15).

Classification

Due to so many different symptoms, which are by far not all expressed in every single patient, a number of classifications were proposed for PC. For clinical purposes the classification proposed by Kumer

and Loos in 1935 (8) is suitable. According to it three groups of patients are recognized: Type A: thickened nails, hypekeratoses of palms and soles, follicular hyperkeratosis. Type B: same symptoms as in Group A plus leukokeratosis linguae and mucosae buccalis. Type C: same symptoms as in B and additional symptoms as dyskeratosis corneae, cataracta and others.

Other classifications which deserve to be mentioned are those by Schönfeld (16), Sivasundram (17) and Feinstein et al (12). Certain authors believe that the designation pachyonychia congenita includes two distinct syndromes: Jadassohn-Lewandowsky in which leukokeratosis appears and that of Jackson-Lawler, characterized by natal teeth, epidermoid cysts, a possible corneal dystrophy but without oral leukoplakia (17 a).

Based on their observations of 36 patients with PC, Kansky et al propose that symptoms in PC should be divided in major ones which are more frequent (palmar and plantar keratosis, thickened nails, follicular hyperkeratosis and hyperhidrosis) and minor symptoms as leukokeratosis, blisters as well as other rare manifestations (18).

Incidence

The PC being rare no data on the incidence in various populations are available. As this condition is relatively frequently encountered in the Slovenian population the incidence has been calculated.

In Slovenia 14 cases were described in a population of 1.86 million which gives an incidence of 0.7 per 10⁵ inhabitants. For Croatia the analogous values

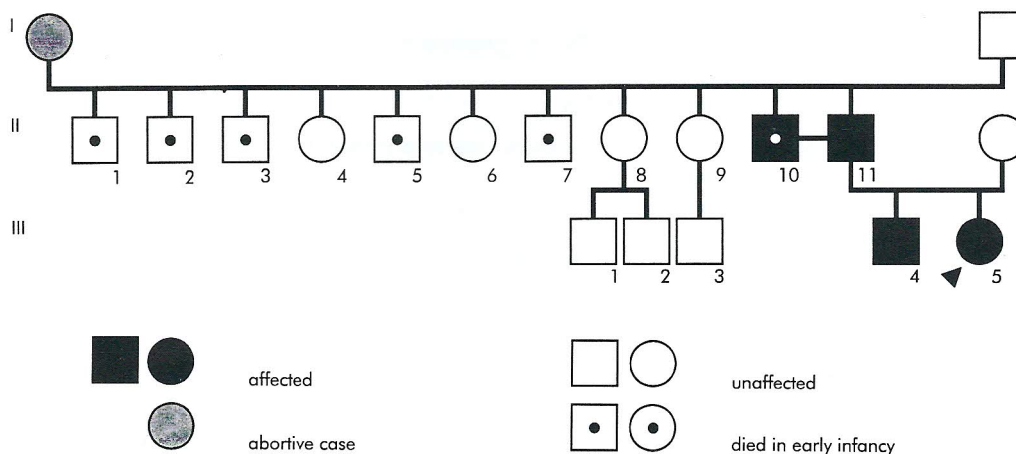


Fig. 1. Genealogical tree of family O with *Pachyonychia congenita*

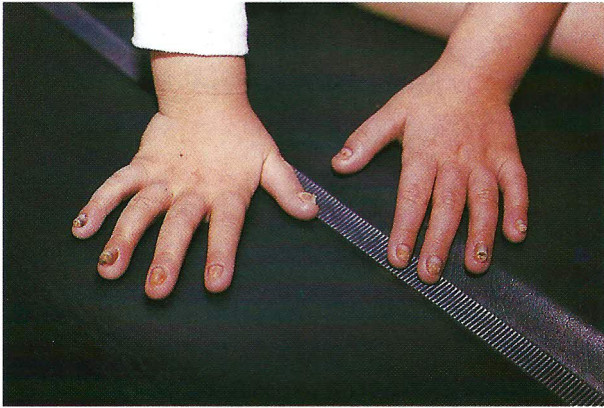


Fig. 2. Patient O III/5. Thickened nails at the age of 1 1/2 year.

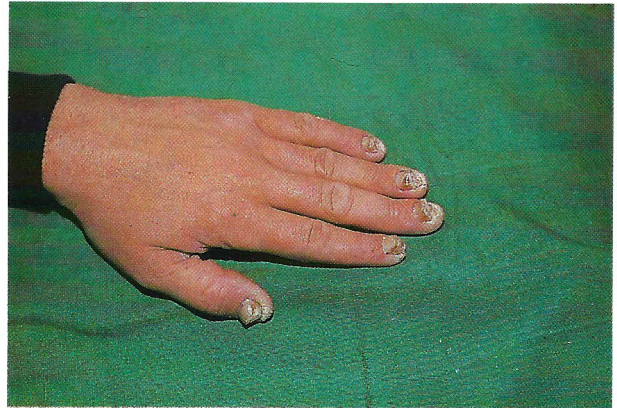

Fig. 3. Patient O II/11. Thickened nails at the age of 39 years.

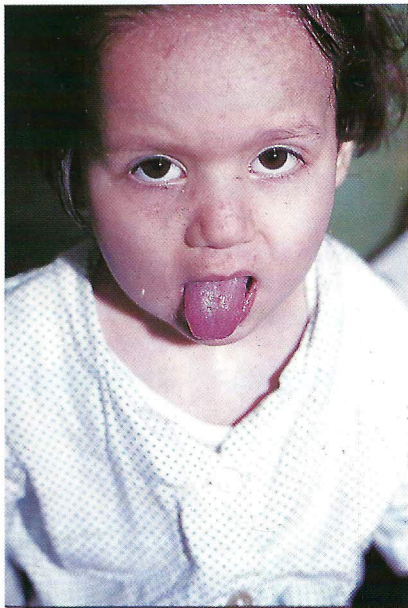

Fig. 4. Patient O III/5. Leukokeratosis of the tongue at the age of 1 1/2 year.

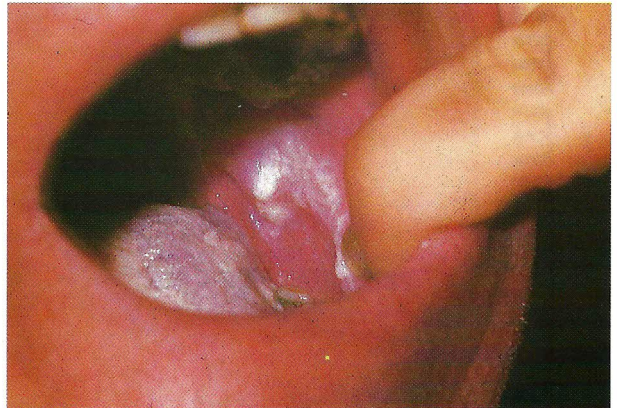


Fig. 5. Patient O II/11. Leukokeratosis of the buccal mucosa and tongue at the age of 39 years.

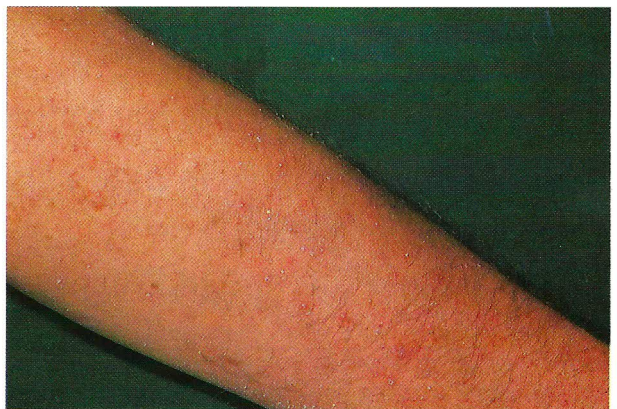

Fig. 6. Patient O II/11. Follicular hyperkeratosis.

are 25 cases in 4.7 million which gives an incidence of 0.53 per 10⁵ (10,11).

Genetics

The majority of authors consider that PC is caused by a mutation of a dominant autosomal gene (1,6,8,12), but, certain authors as Su (9) and Paller (15) are stressing a variable expressivity and an incomplete penetration. Although in many pedigrees a clear dominant inheritance is expressed there are pedigrees in which missing links are traceable and there are also isolated cases reported. For this reason different ways of inheritance are also mentioned in the literature. Cockayne (19) in 1933 and later Cosman (20) supposed that two genes were necessary for the expression of the disease, while Haber and Rose (14) accept even autosomally recessive inheritance.

There are a few serious objections to the simple autosomal mode of inheritance in PC:

1. almost all pedigrees of PC patients are short
2. missing links are relatively frequent in the pedigrees
3. there is a number of isolated cases
4. the ratio of affected to nonaffected family members which should be close to 1:1 was reported by Cockayne as 1:1.78 and in our observation it was even 1:4.48
5. according to our observations in Slovenia and Croatia these patients originate from regions where people for centuries used to live in a secluded way and were marrying in the same or neighboring villages.
6. it is also interesting to note that in large nations PC is extremely rare.

The above listed observations are suggesting that the probability that two genes necessary for expression of PC being present in a patient, are rather low. In such a way our experience support Cockayne's assumption of two autosomally dominant genes determining the PC (19). However we have to wait until the problem will be solved by molecular biologists.

Micromorphology

Histopatology of the hyperkeratotic lesions of palms and soles in PC is closely related to the observations made in the HPPK Unna-Thost: hyperkeratosis, hypergranulosis, acanthosis, increased number and dilatation of capillaries in the papillary layer. Electron microscopic investigations revealed that the intercellular spaces of str. corneum are filled up with a clear

homogeneous mass as well as with remnants of keratinosomes and desmosomes 21. An increased number of tightly packed tonofillaments, enlarged and bizarre shaped keratohyline granules and many keratinosomes were observed in the cells of the granular layer. The sweat ducts were lined up with normal cells which were however surrounded by a few layers of keratinized cells.

The relatively rare blister formation is initiated by a steadily increasing perinuclear vacuolization in the cells of the upper Malpighian layer which results in the formation of an intraepidermal blister.

The thickening of the nail plate starts in the matrix of the nail bed. Histological examination of the affected nails shows a marked increase in the thickness of the nail bed. Microradiographic investigations demonstrated an at least triple augmentation of the dry substance per volume unit inside the nail bed: normally this dry substance amounts to 0.2-0.3 g/cm³, whereas in PC it exceeds 0.6 g/cm³ (22).

Keratinization

Keratins are intermediate filament proteins which constitute the cytoskeleton of all epithelial cells. Over 30 such proteins are known and each is coded by a separate gene. They can be subdivided into two distinct classes on the basis of their migration in two-dimensional electrophoresis, their expression in different cell types and of their sequence homology. Type I keratins (K10 - K 19) are smaller (40-56,5 kD) and relatively acidic, whereas type II keratins (K1 - K9) are larger (58-68 kD) and more basic. Usually keratins are expressed in pairs consisting of one type I and one type II polypeptide. The cluster of genes determining the type I keratins is located on chromosome 17 and that determining type II keratins on chromosome 12.

Keratins K5 and K14 are present in the basal cell layer while in the differentiating epidermal cells K1 and K10 are expressed. In nonkeratinizing squamous epithelia the cytoskeleton of the suprabasal maturing cells is formed from K3 and K14. During the last few years reports have been published suggesting that when keratin filament formation is perturbed in epidermal cells in transgenic animals, the keratinocytes become fragile and prone to rupture upon mild physical trauma (23). In hereditary epidermolysis bullosa (EBH) simplex a basal cell cytolysis occurs upon mechanical stress. It was discovered that patients with EBS have point mutations in the coding segments

of the genes encoding the basal epidermal keratins K5 and K14 (24,25,26).

Epidermolytic hyperkeratosis (erythrodermia ichthyosiformis bullosa, EH) is another autosomal dominant, blistering skin disease characterized by mechanical stress-dependent suprabasal cell cytolysis. In this keratin disorder point mutations in the differentiation-specific keratins K1 and K10 are involved (27,28). It was shown that mutations involving the rod domain are often deleterious to keratin filament network (29).

Although great efforts are being made less exact-information is available on molecular biology of HPPK. One of the reasons is the polymorphism of the respective keratin genes. Wild and Mischke (30) already in 1986 described keratins K4a, K4b, K5a and K5b, later data on keratins K10a, K10b, K10c and K10d were published (31). Tomić et al (32) who investigated the restriction fragment length polymorphism, were able by using the Msp I endonuclease to observe four alleles of keratin 5 which they designated as a, b, c and d. Recently Rogaev et al (33) reported that they were able to map the causative genetic defect in HPPK to an 8 cM interval on chromosome 17 q12-24 or close to the keratin I type cluster.

Lately it was published that K 16 is a candidate gene responsible for anomalies of keratinization in non epidermolytic palmo-plantar hereditary keratodermas (34).

Differential diagnosis

It is a long standing observation that thickened nails may be expressed in psoriasis, especially in the arthropathic form. Kansky and coworkers observed a thickened nail plate with subungual hyperkeratosis in 18 patients with HPPK Unna-Thost (34). But in the above mentioned conditions the nail plate does not display the thickness and the dark brown color as is observed in PC. Serious diagnostic problems may present certain forms of EBH dystrophica dominans with onychogryphosis as it was mentioned by Cockayne (19).

Follicular hyperkeratosis in PC has to be differentiated from keratosis pilaris, phrynoderma, from folliculitis in ichthyosis, pityriasis rubra pilaris or Darier's disease as well as from further similar conditions. Hyperkeratosis of palms and soles in PC should not be mistaken for HPPK Buschke-Fischer-Brauer or for HPPK Unna-Thost.

According to the authors' experience the most difficult problem is the differentiation of PC from

candidiasis of mucous membranes in children and from EBH dystrophica dominans in grown up persons. However taking into account all the relevant symptoms of PC as well as the necessary laboratory tests both the above mentioned conditions can be excluded.

Treatment

There are various methods to treat hyperkeratoses with at least a temporary effect. Unfortunately up to now there is still no efficient procedure for treatment of the thickened nail-plate. A few attempts will be briefly discussed.

LOCAL TREATMENT WITH KERATOLYTICS

- ointment or cream containing 20% salicylic acid with an occlusive dressing
- 3% solution of potassium sulphate and solution of potassium iodate in an equal amount of lanoline applied with occlusive dressing is another possibility for treatment of hyperkeratotic nails.
- Wilkinson (35) suggests a nail avulsion ointment of the following composition

urea	40.0
salicylic acid	20.0
distilled water	30.0 ml
aquaphor	110.0

(aquaphor contains 10% lanolin, 20% petrolatum, 30% mineral oil and 40% water).

Surgical avulsion of the nail under local or general anesthesia is a further possibility, but unless matrix has been removed the nail will regrow in the same shape. Cosman (20) proposed that the nail bed and matrix should be removed and the wound covered with a skin implant. Some patients preferred such solution to the abnormally thickened nail plate. X-ray treatment has also been applied, evidently without encouraging results (37).

SYSTEMIC TREATMENT

Etretinate or etretin were used in patients with PC by various authors. During the treatment the palmar and plantar hyperkeratoses have disappeared but recurred soon after the treatment was stopped. The nails were not influenced essentially

Presentation of a family with pachyonychia congenita

In order to make the presentation of PC more feasible a Slovenian family with PC is described.

Patient II/11 and both of his children III/4 and III/5 have typical clinical symptoms of PC. According to the history given by II/11, his mother (I/1) had a certain degree of palmoplantar keratoderma and most probably a thickened left toe nail. She gave life to 11 children, 5 of them died in childhood. Patient II/11 remembers his mother telling, him that his twin-brother who died in early infancy, also had thickened nails, however the other 9 siblings displayed no such symptoms.

In all three patients II/11, III/4 and III/5 typical symptoms were expressed: pachyonychia, follicular hyperkeratosis, insular hyperkeratosis of palms and soles with blistering in summertime, hyperhydrosis as well as leukokeratosis of the buccal mucosa and of the tongue. The patient II/11 was 38-year old at the time of the first consultation, III/4 was four and a half and III/5 one and a half. They were invited for a check up 20 years later.

REFERENCES

1. Schnyder UW, Klunker W: Erbliche Verhornungsstörungen der Haut Jadassohn J. Handbuch der Haut und Geschlechtskrankheiten Ergänzungswerk. VII, Springer, Berlin 1966, p 905-908.
2. S. Touraine A. L'herédité en médecine. Masson. Paris 1955, p 448-449.
3. Müller C. On the causes of congenital onychogryphosis. München Med Wochenschr 1904; 49: 2180-82.
4. Wilson AG. Three cases of hereditary hyperkeratosis of the nail bed. Br J Dermatol 1905; 17: 13-14.
5. Jadassohn J, Lewandowsky F. Pachyonychia congenita. Keratosis disseminata circumscripta (follicularis). Tyломата. Leukokeratosis linguae. In Jacobs Ikonographia Dermatologica. Berlin: Urban und Schwarzenberg, 1906, Vol I p 29-30.
6. Moldenhauer E, Ernst K. Das Jadassohn-Lewandowsky syndrom. Hautarzt 1968; 19:441-47.
7. Puente JJ. Hereditäre familiäre Pachyonychie. Zbl Haut Geschl Kr 1955; 50:309.
8. Kumer L, Loos HO. Congenital pachyonychia (Riehl type). Wien Klin Wochenschr 1935; 48:174-78.
9. Su WP, Chun SI, Hammond DE, Gordon M. Pachyonychia congenita a clinical study of 12 cases and review of the literature. Pediatr Dermatol 1990; 7: 35-38.
10. Franzot J, Kansky A, Kavčič Š. Pachyonychia congenita (Jadassohn-Lewandowsky syndrome). A review of 14 cases in Slovenija. Dermatologica 1981; 160: 462-72.
11. Videnić N, Kansky A, Basta-Juzbašić A. Pachyonychia congenita (Jadassohn-Lewandowsky syndrome). A review of 25 cases in Croatia. Acta Derm Jug 1991; 18: 173-80.
12. Feinstein A, Friedman J, Schewach-Millet M. Pachyonychia congenita. J Am Acad Dermatol 1988; 19: 705-11.
13. Diaso FA. Pachyonychia congenita Jadassohn: a variety of ichthyosis (Pachyonychia ichthyosiformis) involving chiefly the nails. Arch Derm Syph 1934; 30: 218-26.
14. Haber RM, Rose TH. Autosomal recessive pachyonychia congenita. Arch Dermatol 1986; 122: 919-23.
15. Paller AS, Moore JA, Scher R. Pachyonychia congenita tarda. A late-onset form of Pachyonychia congenita. Arch Dermatol 1991; 127: 701-03.
16. Schönfeld PHIR. The Pachyonychia congenita syndrome. Acta Derm Venereol (Stockh) 1980; 60: 45-49.
17. Sivasundram A, Rajagopalan K, Serojini T. Pachyonychia congenita. Int J Dermatol 1985; 24: 179.
- 17 a. Gorlin RJ, Pindborg JJ, Cohen MM. Syndromes of the Head and Neck. Mc Graw-Hill, New York 1976, p 600-603.
18. Kansky A, Basta-Juzbašić A, Videnić N, Ivanković D, Stanimirović A. Pachyonychia congenita (Jadassohn-Lewandowsky syndrome)-evaluation of symptoms in 36 patients. Arch Dermatol Res 1993; 285: 36-37.
19. Cockayne EA. Inherited abnormalities of the skin and its appendages. Oxford University Press, London, 1933.
20. Cosman B, Symonds FC, Crikelair GF. Plastic surgery in pachyonychia congenita and other dyske-

- ratoses. Case report and review of the literature. *Plast Reconstr Surg* 1964 33: 226-38.
21. Thorman J, Kobayasi T. Pachyonychia congenita Jadassohn -Lewandowsky a disorder of keratinization. *Acta Derm Venereol* (Stockh) 1977; 57: 63-67.
22. Forslind B, Nylen B, Swanbeck G, Thyresson M and Thyresson N. Pachyonychia congenita, A histologic and Microradiographic Study - *Acta Derm Venereol* (Stockh) 1973; 53: 211-16.
23. Vassar R, Coulombe PA, Degensteine R et.al. Mutant Keratin expression in transgenic mice causes marked abnormalities resembling a human genetic skin disease. *Cell* 1991; 64: 365-85.
24. Coulombe PA, Mutton ME, Lettai A et.al. Point mutations in human Keratin 14 genes of Epidermolysis bullosa simplex patients. *Cell* 1991; 66: 1301-11.
25. Bonifas JM, Rothman AL, Epstein EM sr. Epidermolysis bullosa simplex: evidence in two families for keratin gene abnormalities. *Science* 1991; 254: 1202- 05.
26. Lane E.B. Rugg EL, Nausaria H et. al. A mutation in the conserved helix termination peptide of keratin 5 in hereditary skin blistering. *Nature* 1992; 356: 244-46.
27. Chipev CC, Korge BBP, Markova N, Bale SJ, Di Giovanna JJ, Compton JG, Steinert PM. A leucine-proline mutation in the H1 subdomain keratin K1, causes epidermolytic hyperkeratosis. *Cell* 1992; 70: 821-28.
28. Ishida-Yamamoto A, Mc Grath JA, Judge MR, Leigh IM, Lane EB, Eady RAJ. Selective involvement of keratin 1 and keratin 10 in the cytoskeletal abnormality of epidermolytic hyperkeratosis (bullous congenital ichthyosiform erythroderma) *J Invest Derm* 1992; 99: 19-26.
29. Letai A, Coulombe PA, Mc Cormick MB, Yu QQ, Hutton E, Fuchs E. Disease severity correlates with position of keratin point mutations in patients with EBS. *Proc Natl Acad Sci USA* 1993; 90: 3197-201.
30. Wild GA, Mieschke D. Variation and frequency of cytokeratin polipeptide patterns in human squamous non keratinizing epithelium. *Exp Cell Res* 1986; 162: 114-26.
31. Korge BP, Song-Quing G, Mc Bride W, Mieschke D, Steinert PM. Extensive size polymorphism of the human keratin 10 chain residues in the C-terminal V2 subdomain due to variable numbers and sizes of glycine loops. *Proc Natl Acad Sci USA* 1992; 89: 910-14.
32. Tomić S, Komel R, Kansky A, Blumenberg M. Keratin 5 associated restriction fragment lenght polymorphism in patients with palmoplantar keratoderma of Unna-Thost type. *Acta Dermatovenereol APA* 1992; 4: 114-18.
33. Rogaev EI, Rogaeva EA, Ginter EK, Korovaitseva G , Farrer LA, Shlensky AB, Pritkov AN, Mordovtsev VN, St George-Hyslop PH. Identification of genetic locus for keratosis palmaris et plantaris on chromosomes near the RARA and keratin type I genes. *Nature genetics* 1993; 5: 158-62.
34. Turner R, Watts CE, Marks R and Bowden PE. Mutational analysis of K 16 by genomic PCR-the pseudogene problem. Abstracts, European Society for Dermatological Reseaerch, 24 Annual Meeting, Vienna 1994, p.58.
35. Kansky A, Arzenšek J, Strojjan J et al. Keratoderma palmoplantaris of Unna-Thost type in Slovenia. *Acta Derm Venereol* (Stockh) 1984; 64: 140-42.
36. Wilkinson DS. Formulary of topical applications. In Rook A et al: *Textbook of Dermatology* Blackwell, Oxford, 1986, p 2617.
37. Anderson NP. Pachyonychia congenita in mother and daughter. *Arch Dermatol* 1940; 42: 365.

AUTHORS' ADDRESSES

Aleksej Kansky MD, PhD, professor of dermatology, Dpt Dermatology
Clinical Center, Zaloška 2, 61000 Ljubljana, Slovenia
Marta Penko MD, dermatologist, same address
Zvezdana Milakić-Snoj MD, same address